Clinical Application of Microanatomy In the treatment for Thyroid disorders With Acupuncture

Presented by

Mei Hung Lee Lai, PhD, LAc

www.sbueaa.com

SBUEAA Webinar Course

July 12th, 2025

Introduction of
Thyroid gland

The thyroid gland is a butterfly-shaped endocrine gland located in the front of the neck that produces hormones crucial for regulating metabolism, growth, and development. It primarily secretes triiodothyronine (T3) and thyroxine (T4), which influence various bodily functions, including heart rate, body temperature, cholesterol levels, and energy expenditure.

Hormonal Regulation: The thyroid gland's hormone production is tightly regulated by a feedback loop involving the hypothalamus and pituitary gland. The hypothalamus releases thyrotropin-releasing hormone (TRH), which stimulates the pituitary gland to produce thyroid-stimulating hormone (TSH). TSH, in turn, prompts the thyroid gland to release T3 and T4.

Endocrine gland

Produces and secrets triiodothyronine (T3) and thyroxine (T4).

Metabolism

Thyroid hormones control the speed at which the body uses energy, affecting how the body burns calories and uses nutrients.

Growth & Development

The thyroid gland plays a vital role in normal growth, particularly during childhood and adolescence.

Heart Function

Thyroid hormones influence heart rate and the force of heart contractions, impacting blood pressure and overall cardiovascular health.

Nervous System

Thyroid hormones affect brain development and nerve function, impacting mood, concentration, and cognitive abilities.

Other Functions

Thyroid hormones also influence digestion, muscle tone, skin and hair health, and bone development.

- Hyperthyroidism
- Hypothyroidism
- Goiters
- Thyroid nodules
- Thyroiditis
- Thyroid cancer

Diseases of Thyroid disorders

Thyroid disorders encompass a range of conditions where the thyroid gland doesn't produce the right amount of hormones. These disorders can be broadly categorized as either hyperthyroidism (overactive thyroid) or hypothyroidism (underactive thyroid). Other thyroid conditions include goiters, thyroid nodules, thyroiditis (inflammation), and thyroid cancer.

Thyroid gland

Anatomy

1. Location
2. Shape
3. Surface
4. Relations
5. Vascularization
6. Innervation
7. Lymph Drainage

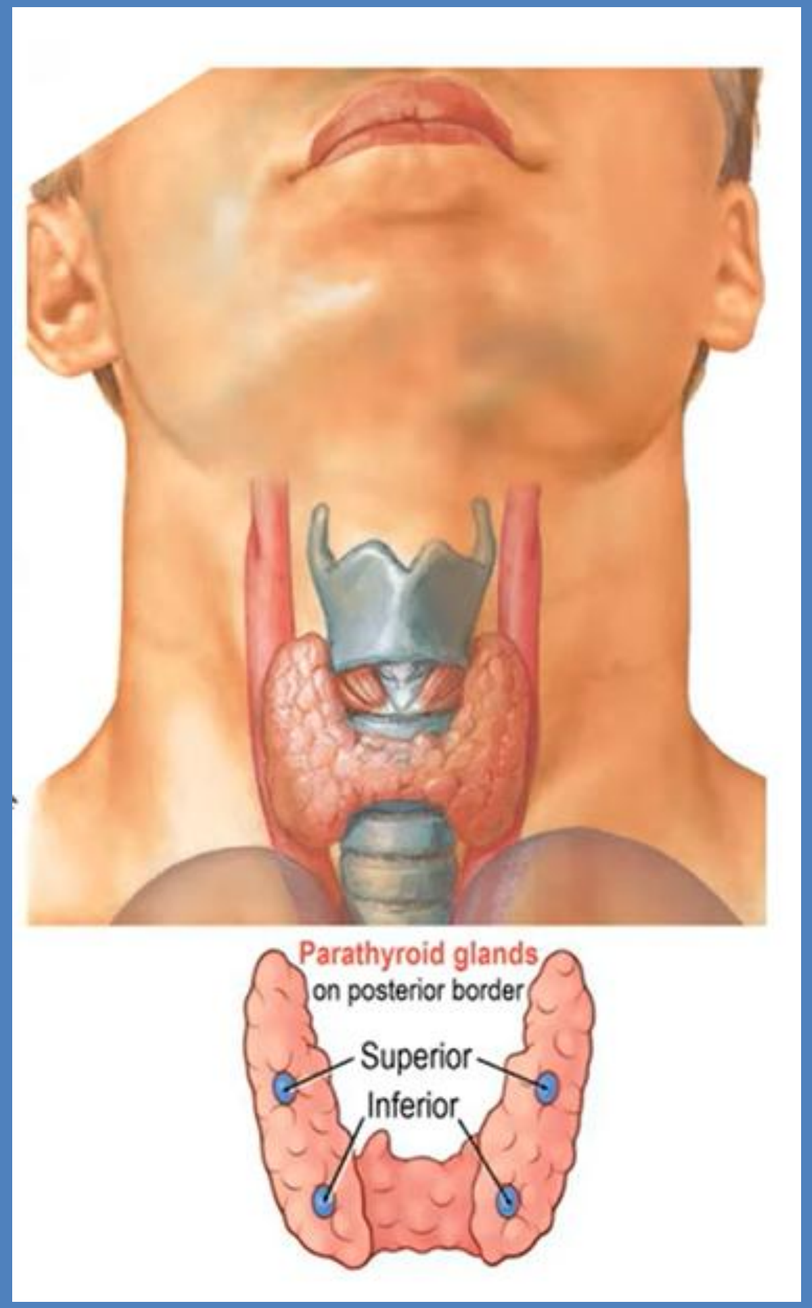

Anatomy of the Thyroid Gland, Dr Adel Bondok Making Anatomy Easy

1. Location of Thyroid gland

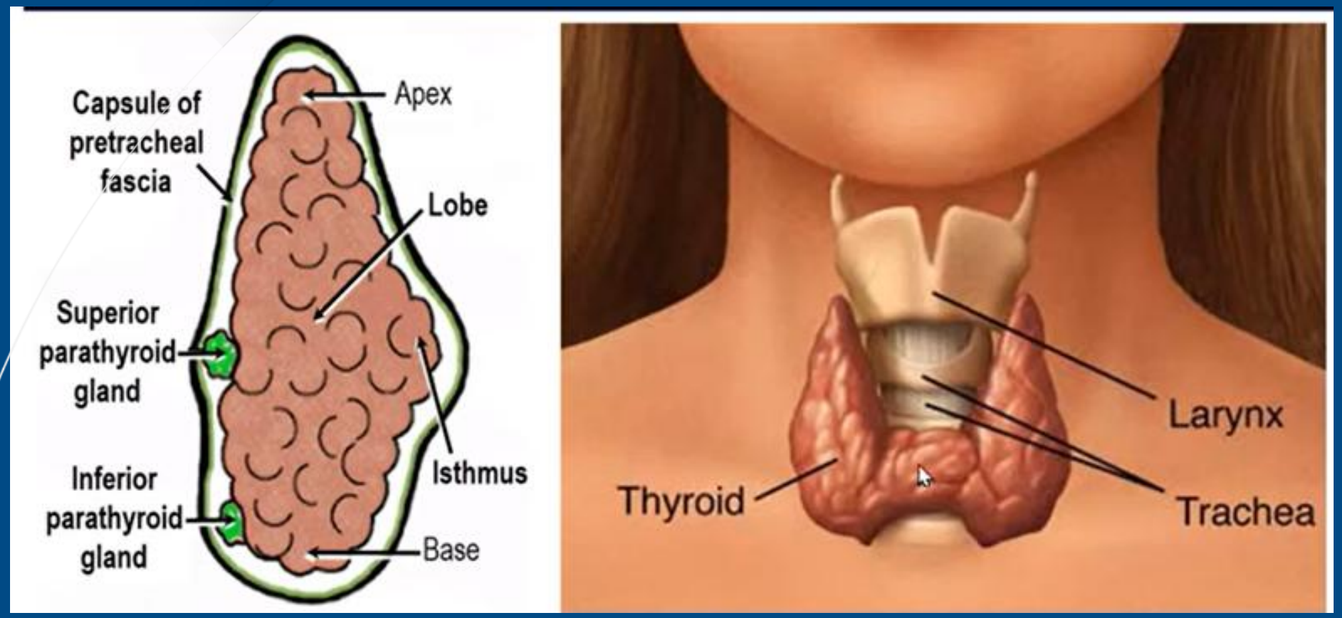

- ✓ In front of the lower part of the neck.
- ✓ Surrounds the front & sides of upper part of the trachea.
- ✓ It is covered by the pretracheal fascia which fixes the gland to the trachea so the gland moves with swallowing.

Anatomy of the Thyroid Gland, Dr Adel Bondok Making Anatomy Easy

2. Shape

- ✓**2 Lobes:** Each lobe extends from the oblique line of thyroid cartilage to the 5th or 6th tracheal ring.
- ✓**The isthmus:** overlies the 2nd, 3rd & 4th tracheal rings.
- ✓It's a small pyramidal lobe may project upward from the upper border of the isthmus.
- ✓It is connected to the hyoid bone by fibrous band called levator glandulae thydoidea. It is remnant of thyroglossal duct.

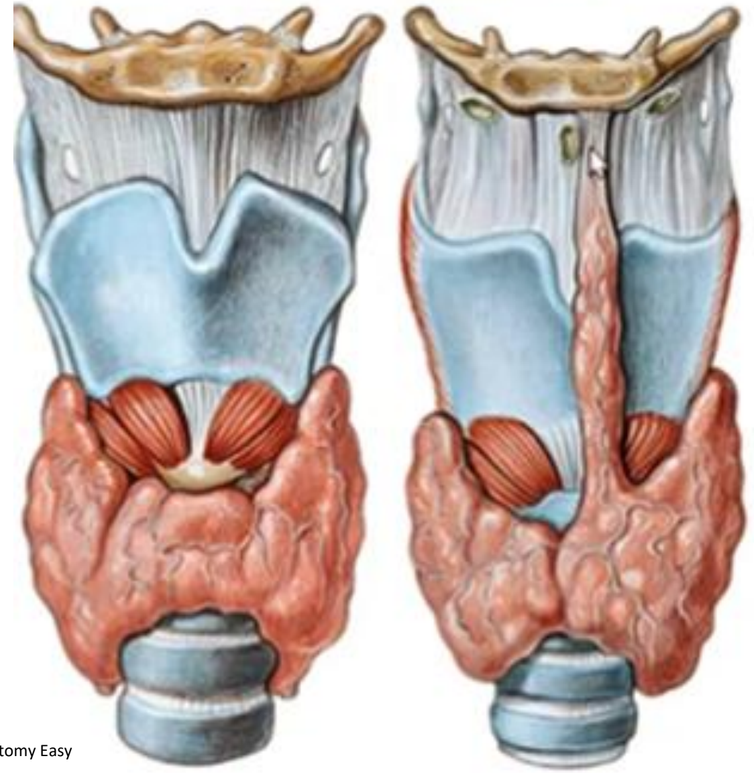

3. Surfaces

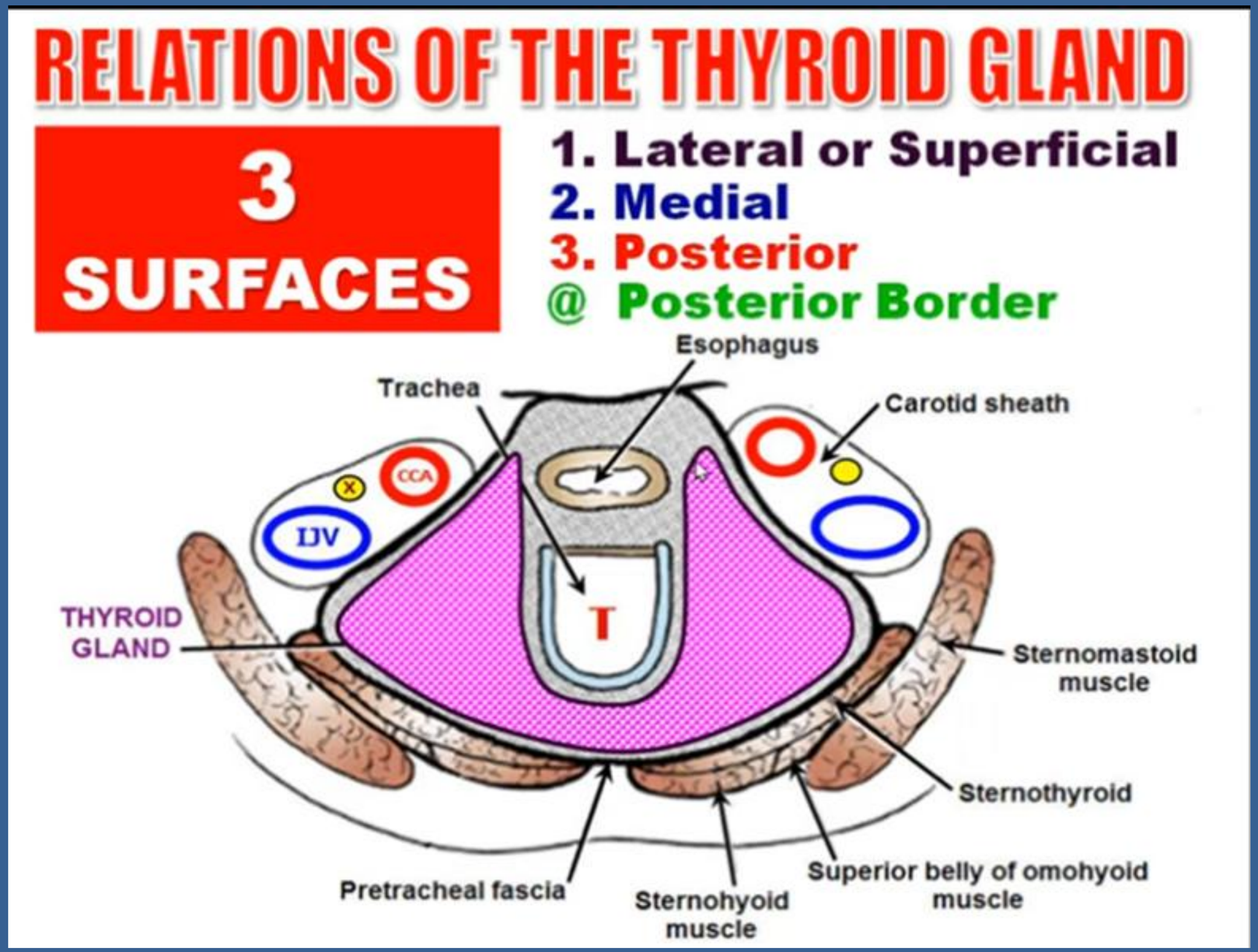

Anatomy of the Thyroid Gland, Dr Adel Bondok Making Anatomy Easy

4. Relations

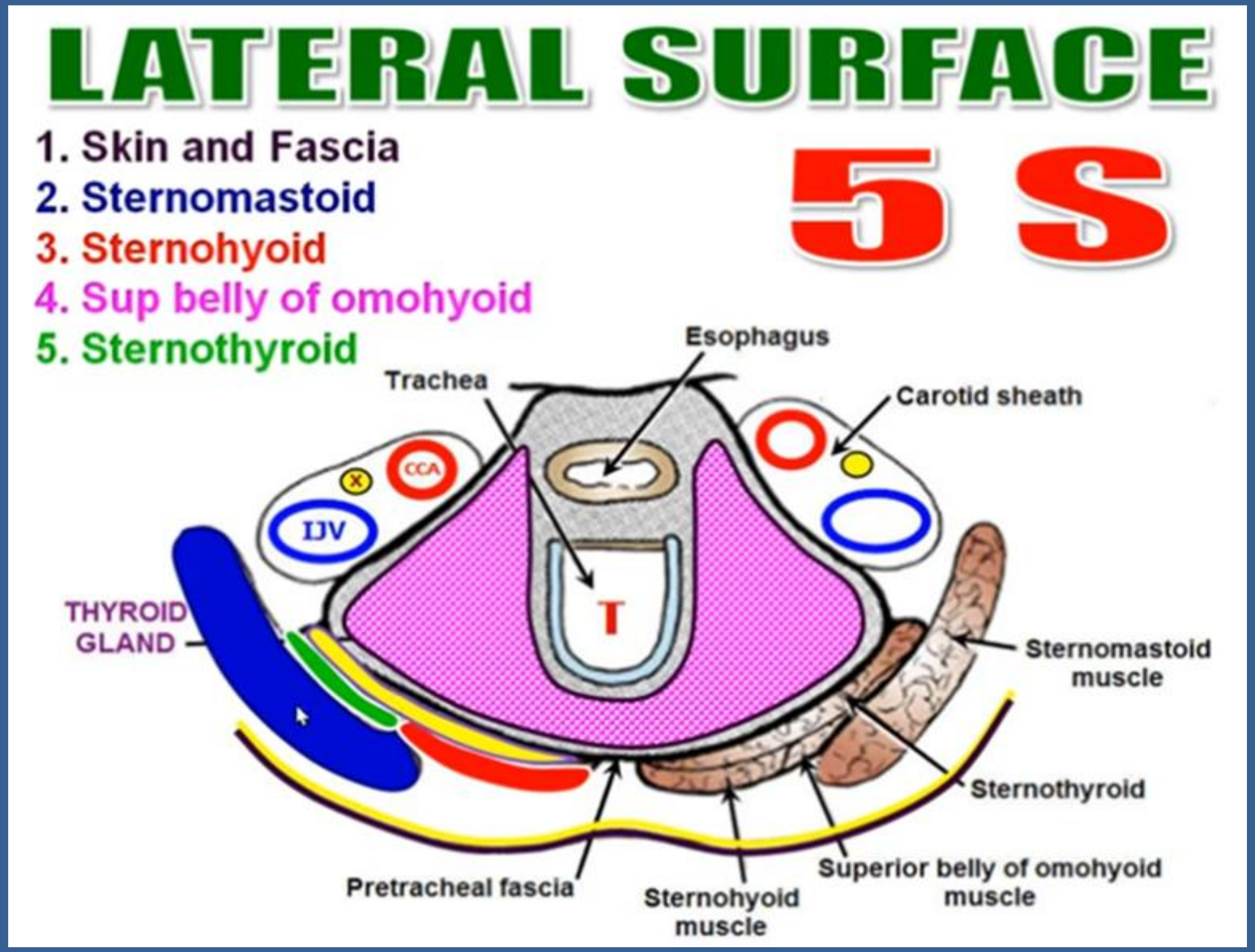

Anatomy of the Thyroid Gland, Dr Adel Bondok Making Anatomy Easy

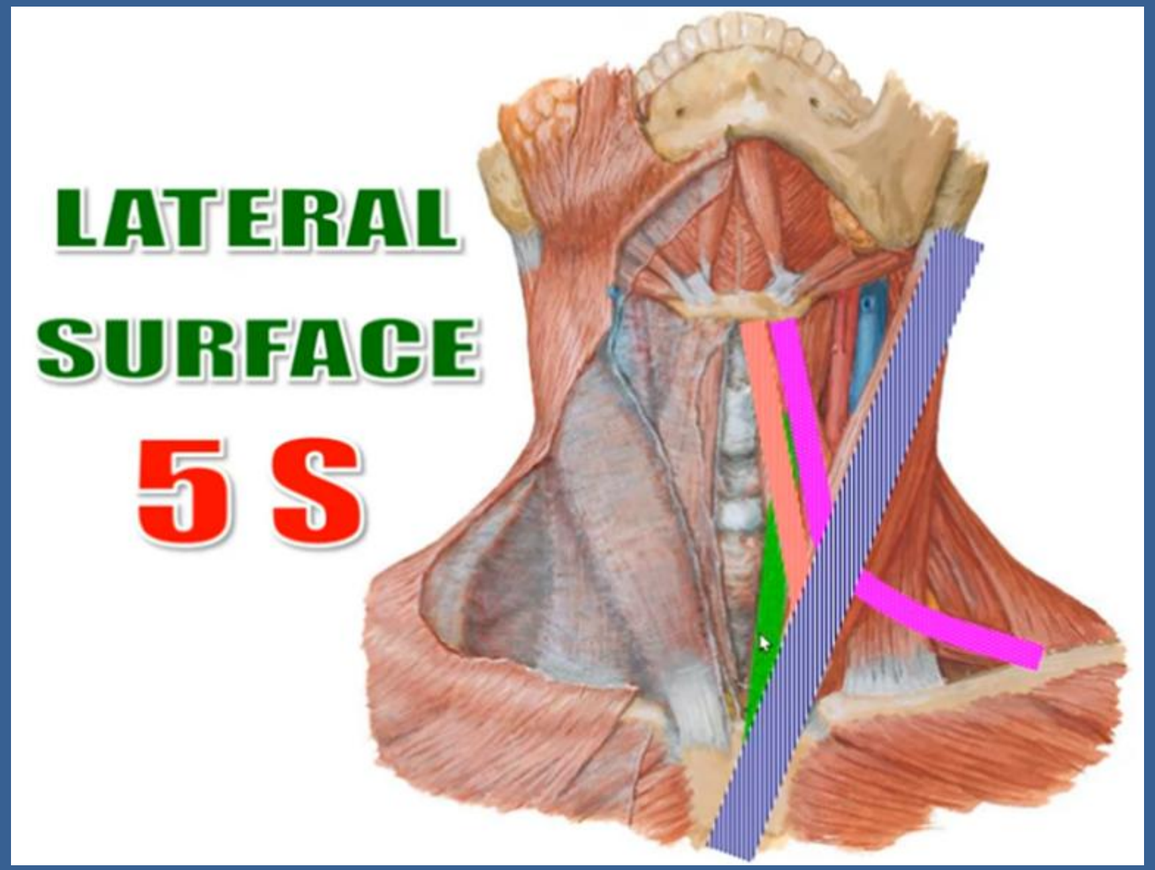

Anatomy of the Thyroid Gland, Dr Adel Bondok Making Anatomy Easy

MEDIAL SURFACE

2 Tubes Above
2 Tubes Below
2 Muscles
2 Nerves

8

- Larynx & Pharynx
- Trachea & Esophagus
- Inferior Constrictor & Cricothyroid Muscles
- External Laryngeal & Recurrent laryngeal Nerves

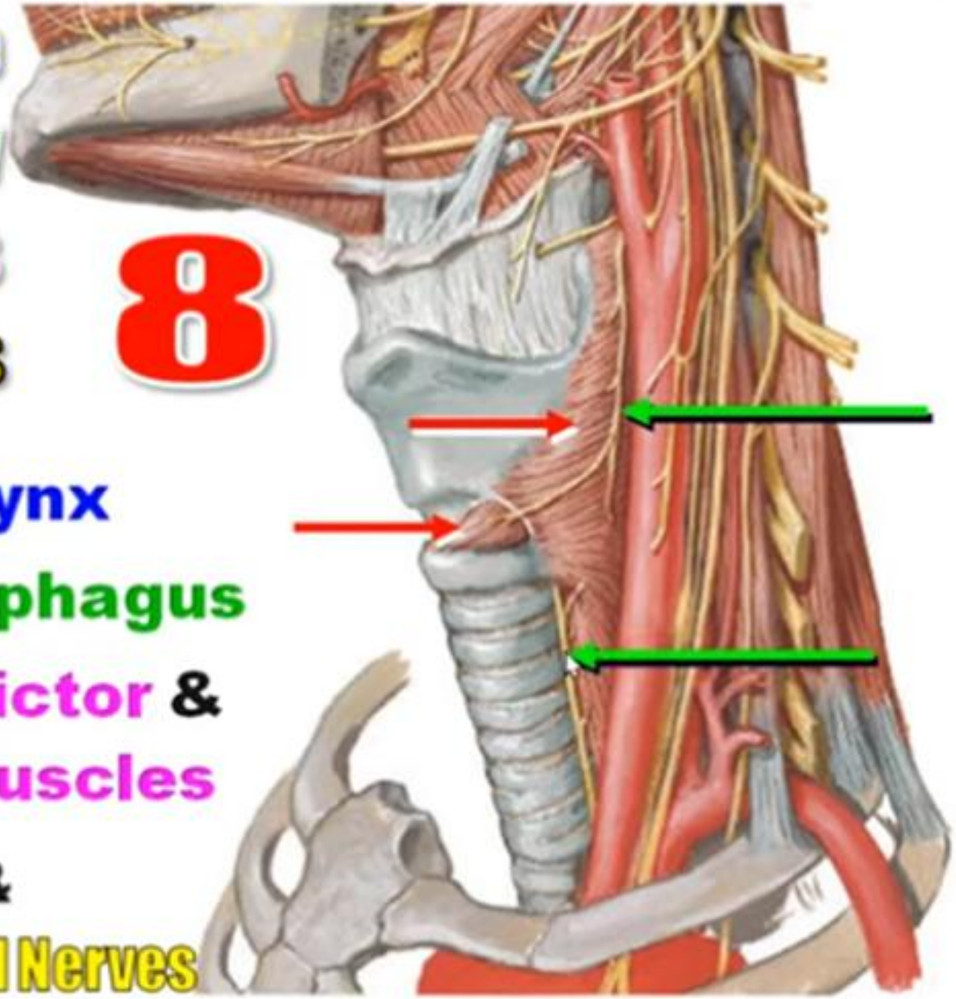

Anatomy of the Thyroid Gland, Dr Adel Bondok Making Anatomy Easy

POSTERIOR SURFACE

1. Carotid Sheath: containing common carotid artery, internal jugular vein & the vagus nerve
2. Sympathetic chain & prevertebral muscles behind carotid sheath

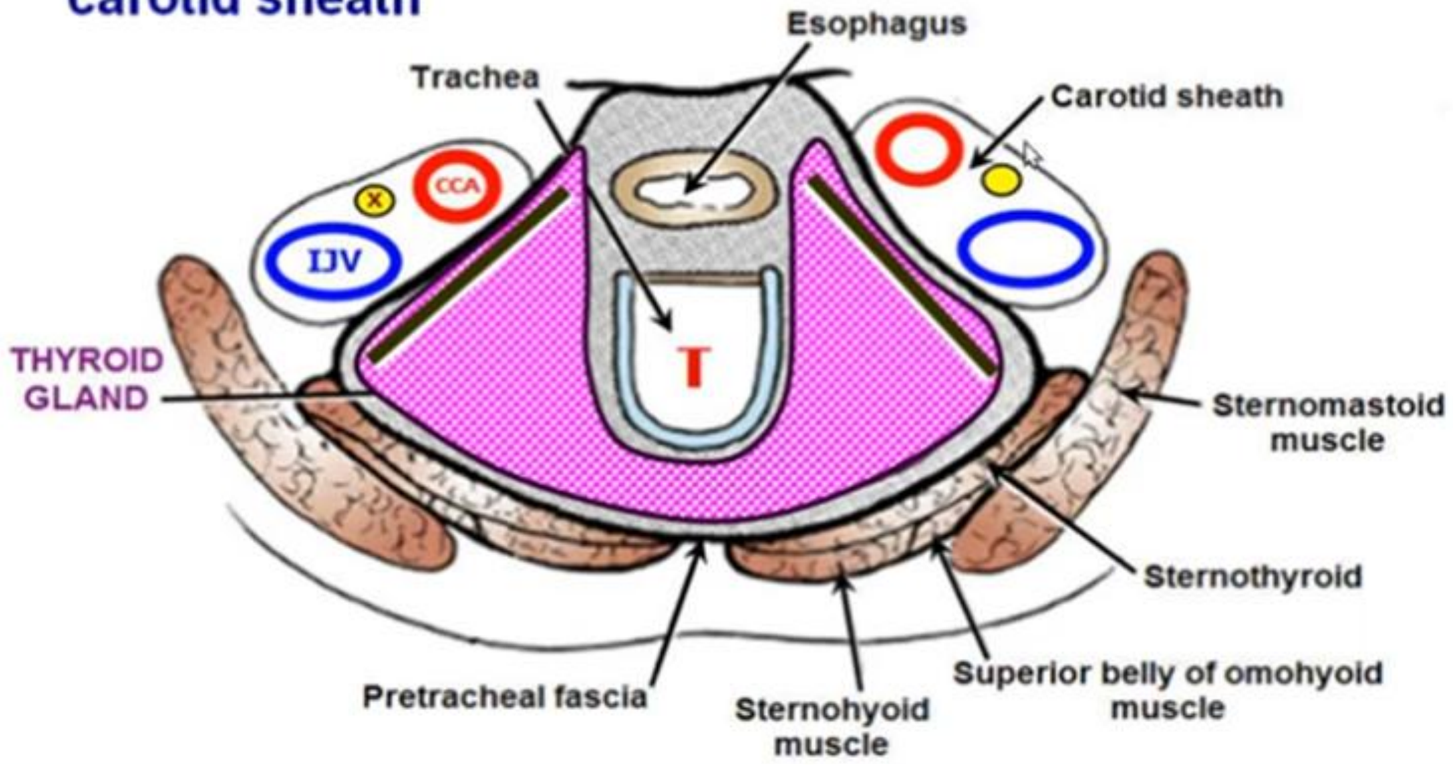

Anatomy of the Thyroid Gland, Dr Adel Bondok Making Anatomy Easy

POSTERIOR BORDER

Superior Parathyroid Gland:
in the middle

Inferior Parathyroid Gland:
at lower end

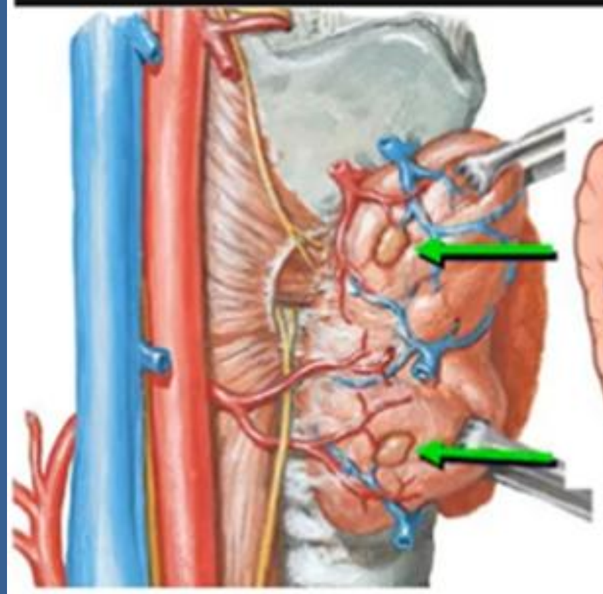

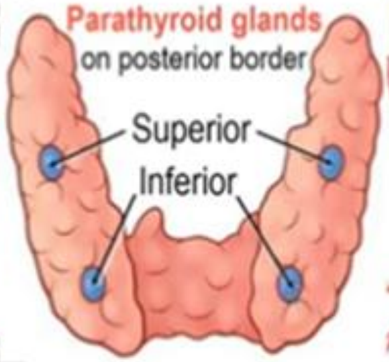

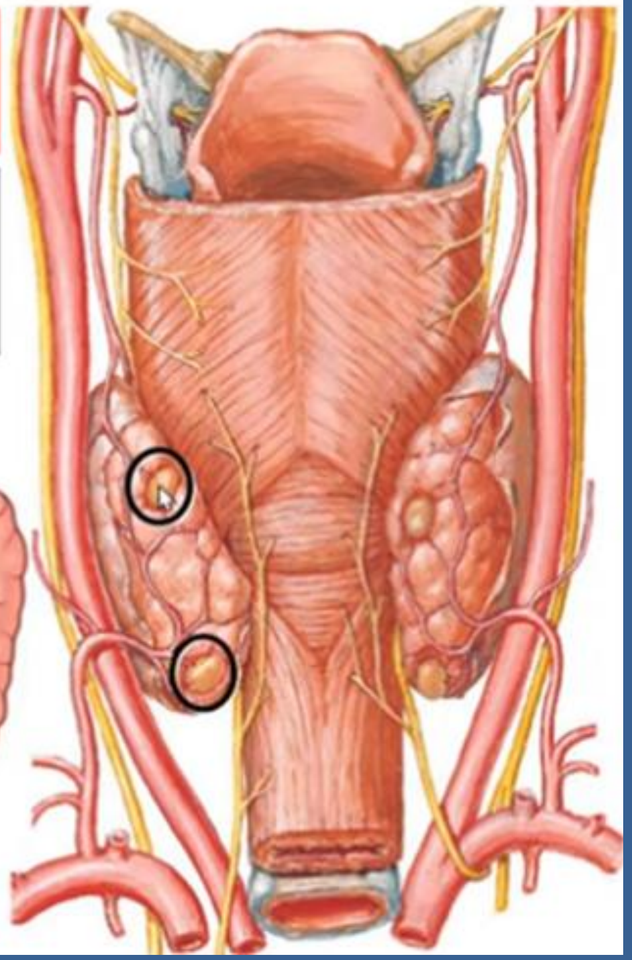

Anatomy of the Thyroid Gland, Dr Adel Bondok Making Anatomy Easy

5. Vascularization

ARTERIAL SUPPLY 3

1. **Superior thyroid artery:** from the external carotid artery
2. **Inferior thyroid artery:** from the thyrocervical trunk **(1st part of subclavian artery)**
3. **Thyroid ima artery:** in 10%. It arises from the aortic arch or the brachiocephalic artery. It supplies the isthmus. Ima = the lowest

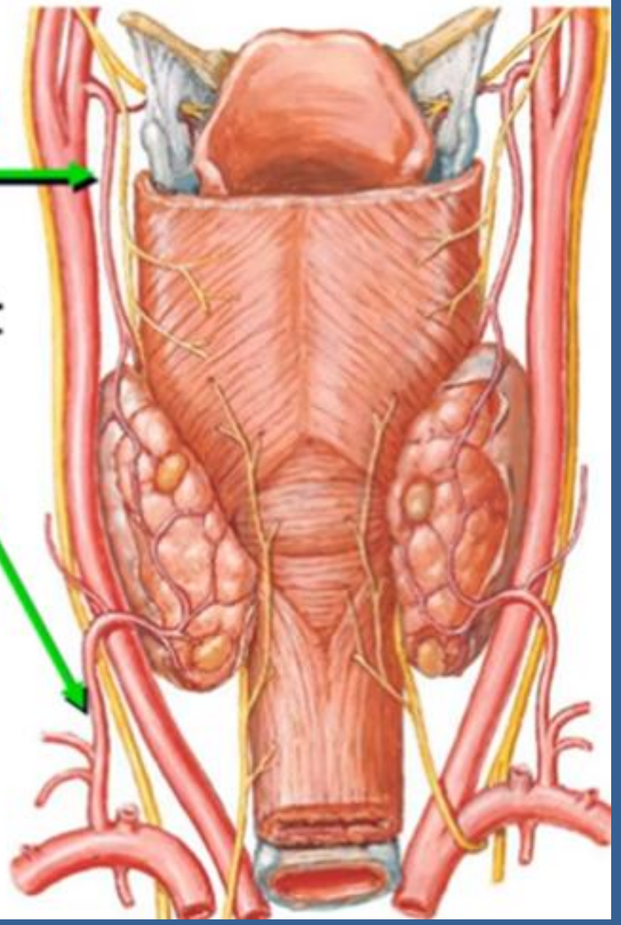

Anatomy of the Thyroid Gland, Dr Adel Bondok Making Anatomy Easy

ARTERIAL SUPPLY

1. Superior thyroid artery:

- Accompanied by the external laryngeal nerve
- Supplies upper 1/3 of the lobe & upper 1/2 of the isthmus

2. Inferior thyroid artery:

- Accompanied by the recurrent laryngeal nerve
- Supplies lower 2/3 of the lobe & lower 1/2 of the isthmus and the parathyroid glands

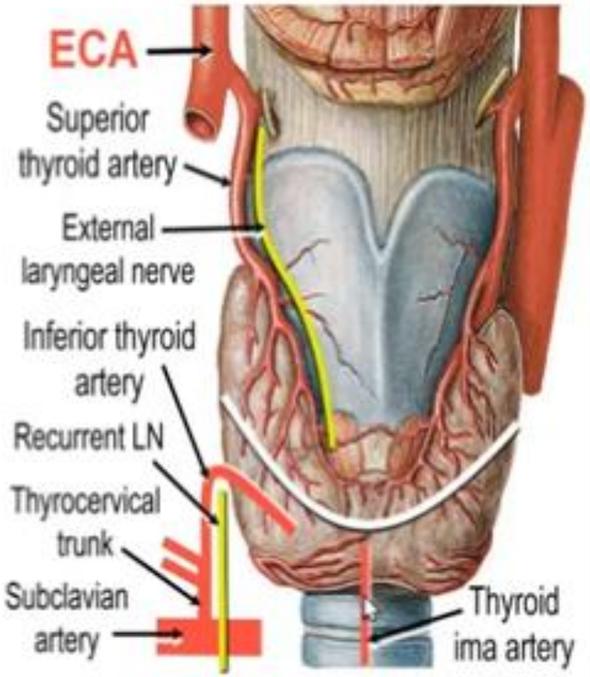

3. Thyroid ima artery: to the isthmus

Anatomy of the Thyroid Gland, Dr Adel Bondok Making Anatomy Easy

VENOUS DRAINAGE

1. **Superior thyroid vein:** ends in the internal jugular vein
2. **Middle thyroid vein:** ends in the internal jugular vein. It is the widest and shortest
3. **Inferior thyroid veins:** ends in the left brachiocephalic vein

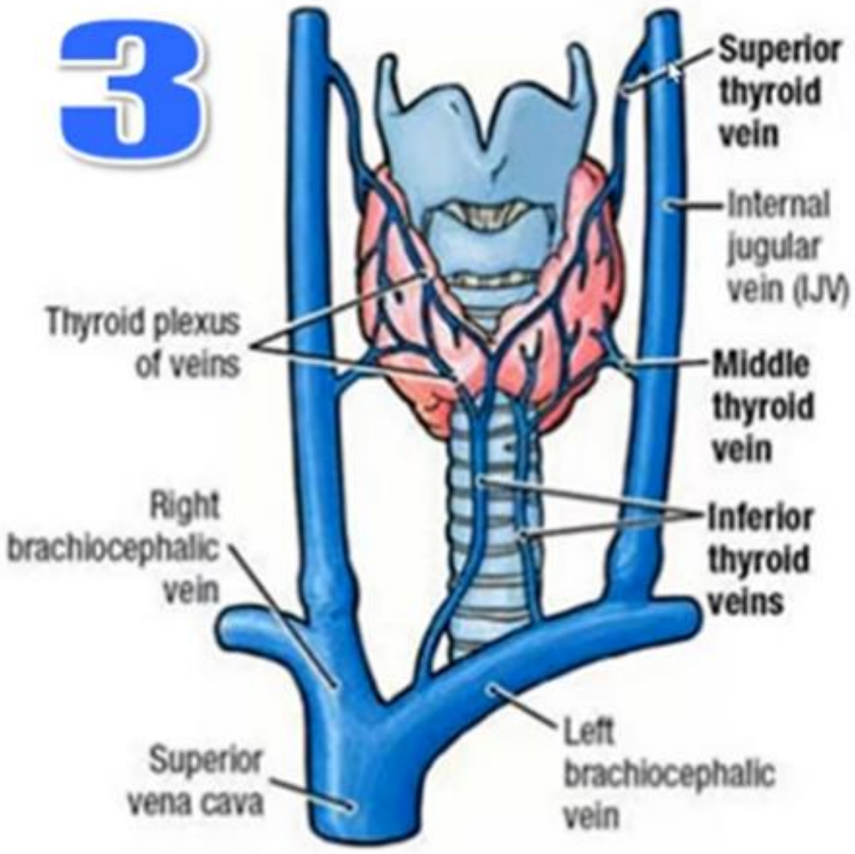

Anatomy of the Thyroid Gland, Dr Adel Bondok Making Anatomy Easy

6. Innervation

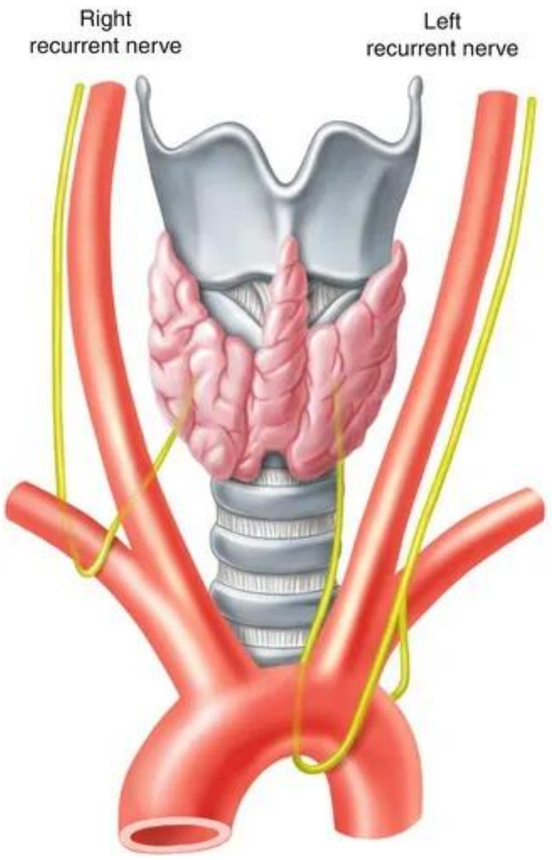

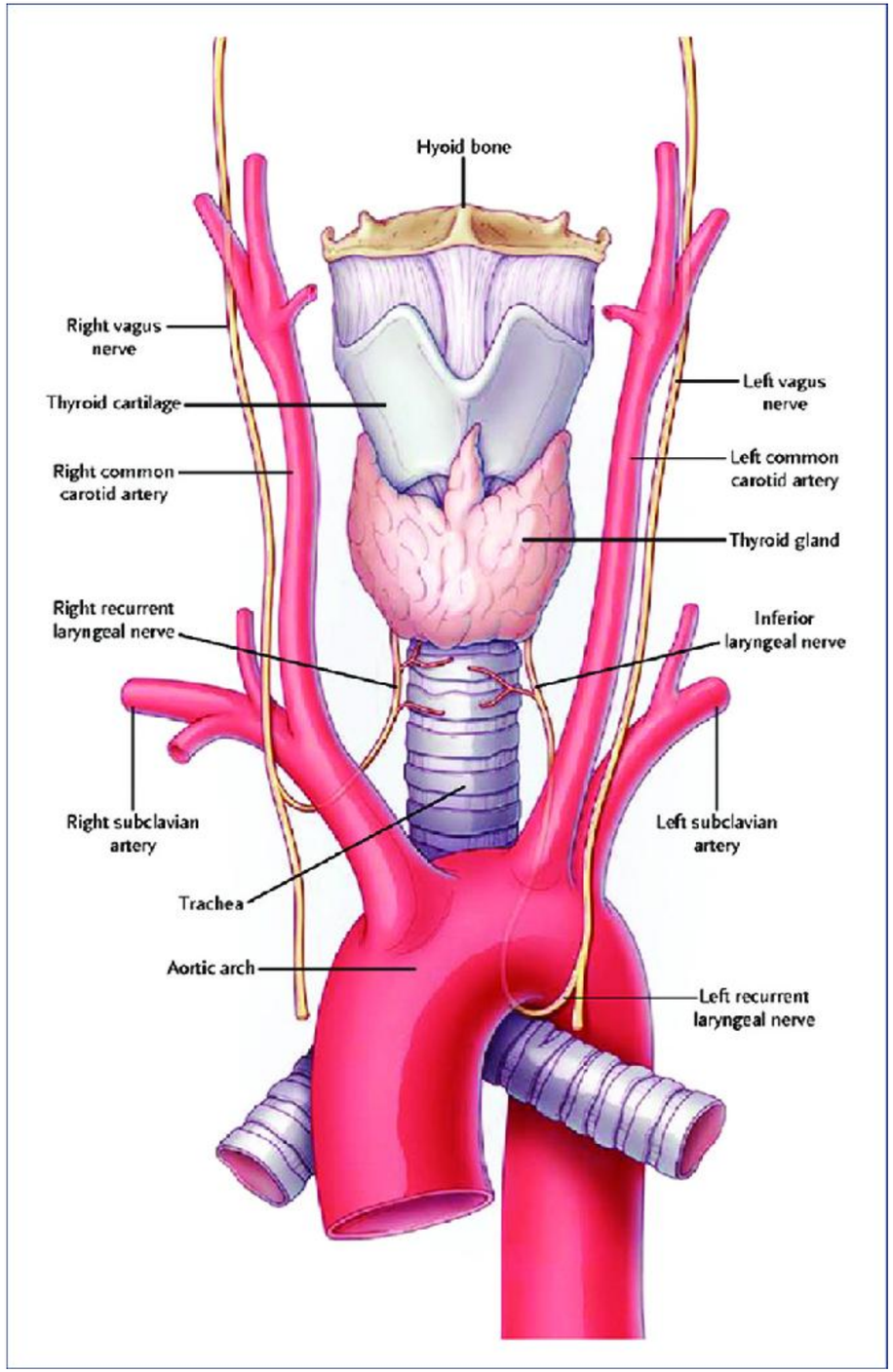

1. Sympathetic Nerves:
Fibers from the superior, middle, and inferior cervical ganglia contribute to the sympathetic innervation of the thyroid. These fibers often travel along blood vessels, particularly the inferior thyroid artery, to reach the gland.

2. Parasympathetic Nerves:
The vagus nerve (cranial nerve X) provides parasympathetic innervation to the thyroid gland. Specifically, branches of the vagus, such as the superior laryngeal nerve and recurrent laryngeal nerve, are involved.

3. Left & Right Recurrent Laryngeal Nerves:
These nerves are particularly important as they are closely associated with the thyroid gland and can be vulnerable during thyroid surgery. Damage to these nerves can affect vocal cord function.

4. Nerve Plexuses:
The sympathetic nerves form plexuses around blood vessels, like the inferior thyroid artery, which then distribute to the gland.

LYMPH DRAINAGE

1. Isthmus:

to the pretracheal lymph nodes

2. Upper Part:

to the upper deep cervical lymph nodes

3. Lower Part:

to the lower deep cervical lymph nodes

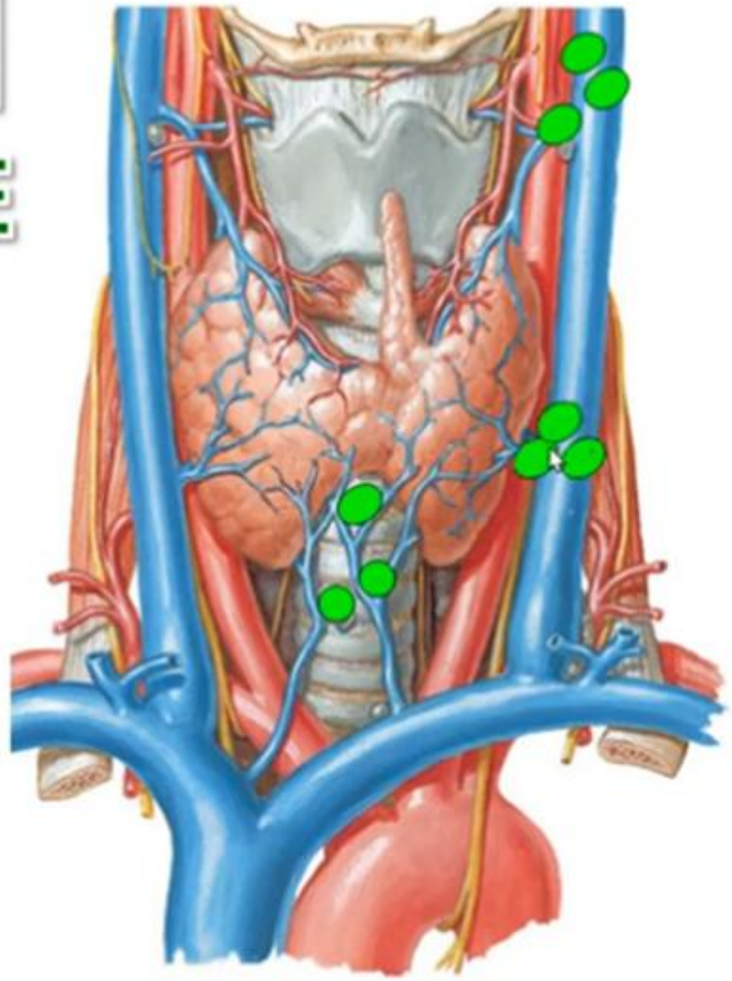

Anatomy of the Thyroid Gland, Dr Adel Bondok Making Anatomy Easy

Clinical Note

2 structures may be injured during thyroidectomy

- Parathyroid Glands
- External & recurrent laryngeal nerves

Dr Adel Bondok®

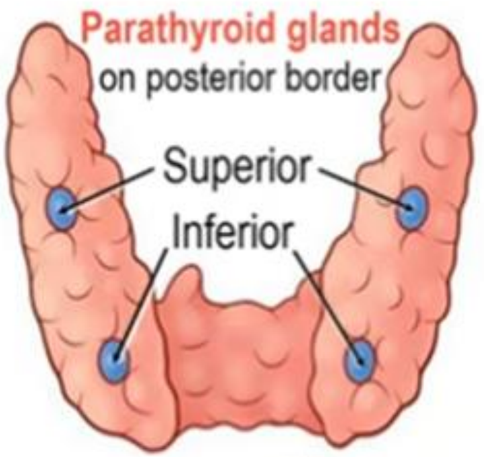

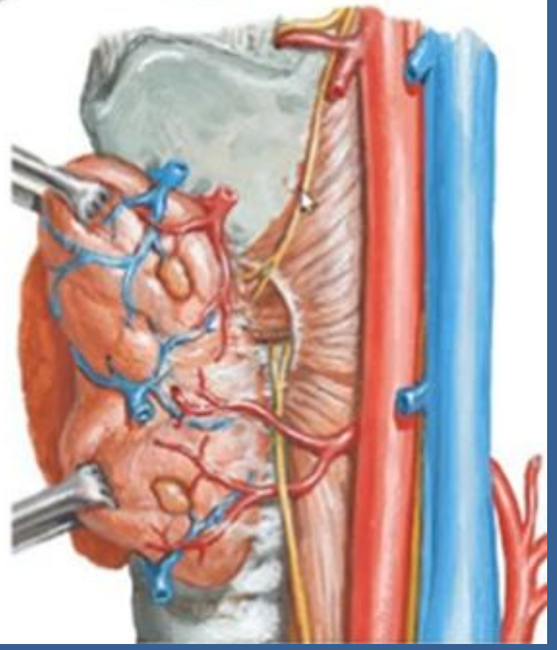

Anatomy of the Thyroid Gland, Dr Adel Bondok Making Anatomy Easy

Clinical Note

Ligation of the thyroid arteries during thyroidectomy

The **superior thyroid artery** is ligated close to the upper pole of the thyroid gland to avoid injury of the **external laryngeal nerve**

Dr Adel Bondok ®

The **inferior thyroid artery** is ligated away from the gland close to its origin to avoid injury of the **recurrent laryngeal nerve**

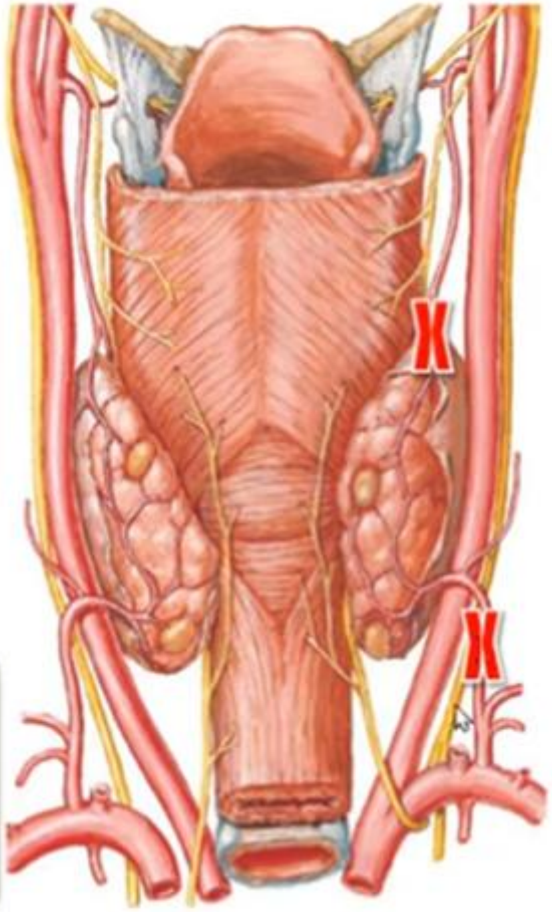


Break
time

PART II

Thyroid gland innervation

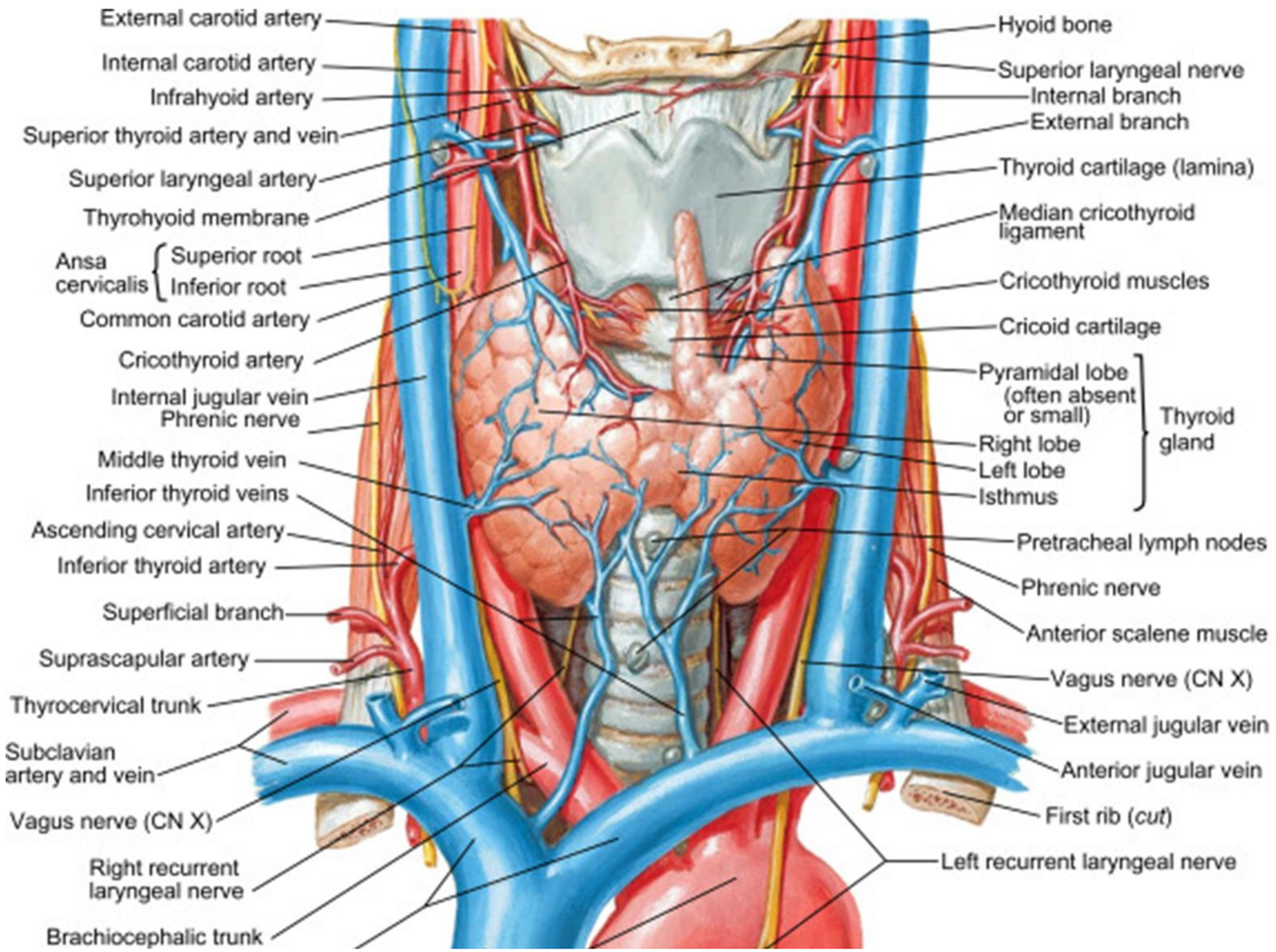

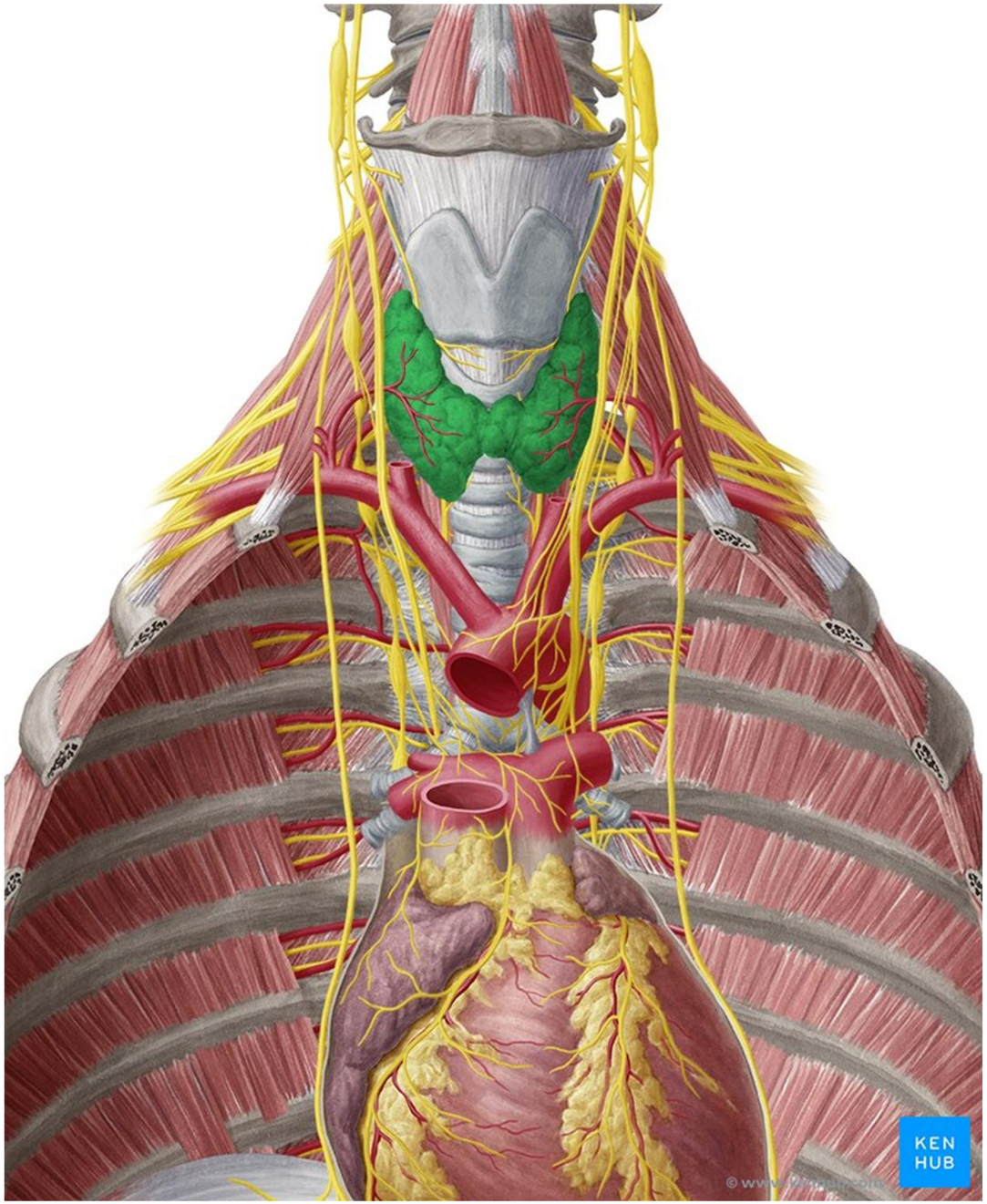

1. Sympathetic Nerves:

Fibers from the **superior, middle, and inferior** cervical ganglia contribute to the sympathetic innervation of the thyroid. These fibers often travel along blood vessels, particularly the inferior thyroid artery, to reach the gland.

2. Parasympathetic Nerves:

The **vagus nerve** (cranial nerve X) provides parasympathetic innervation to the thyroid gland. Specifically, **branches of the vagus**, such as the **superior laryngeal nerve** and **recurrent laryngeal nerve**, are involved.

3. Left & Right Recurrent Laryngeal Nerves:

These nerves are particularly important as they are closely associated with the thyroid gland and can be vulnerable during thyroid surgery. Damage to these nerves can affect vocal cord function.

4. Nerve Plexuses:

The **sympathetic nerves form plexuses** around blood vessels, like the inferior thyroid artery, which then distribute to the gland.

Sympathetic Nerve

交感神经概况

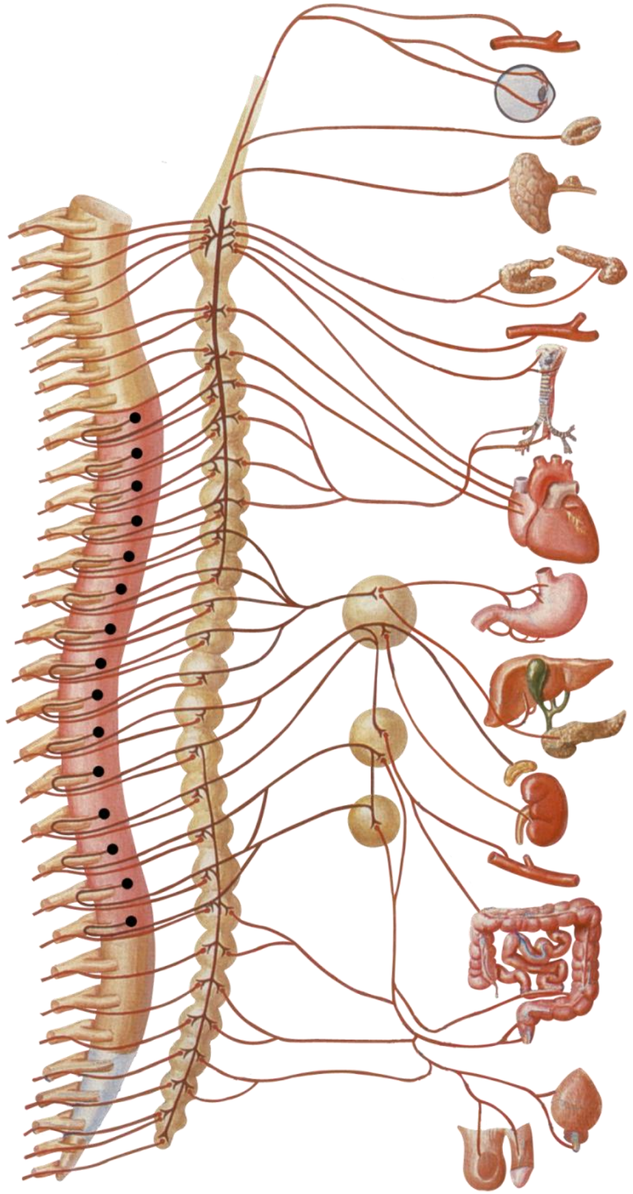

Parasympathetic Nerve

副交感神经概况

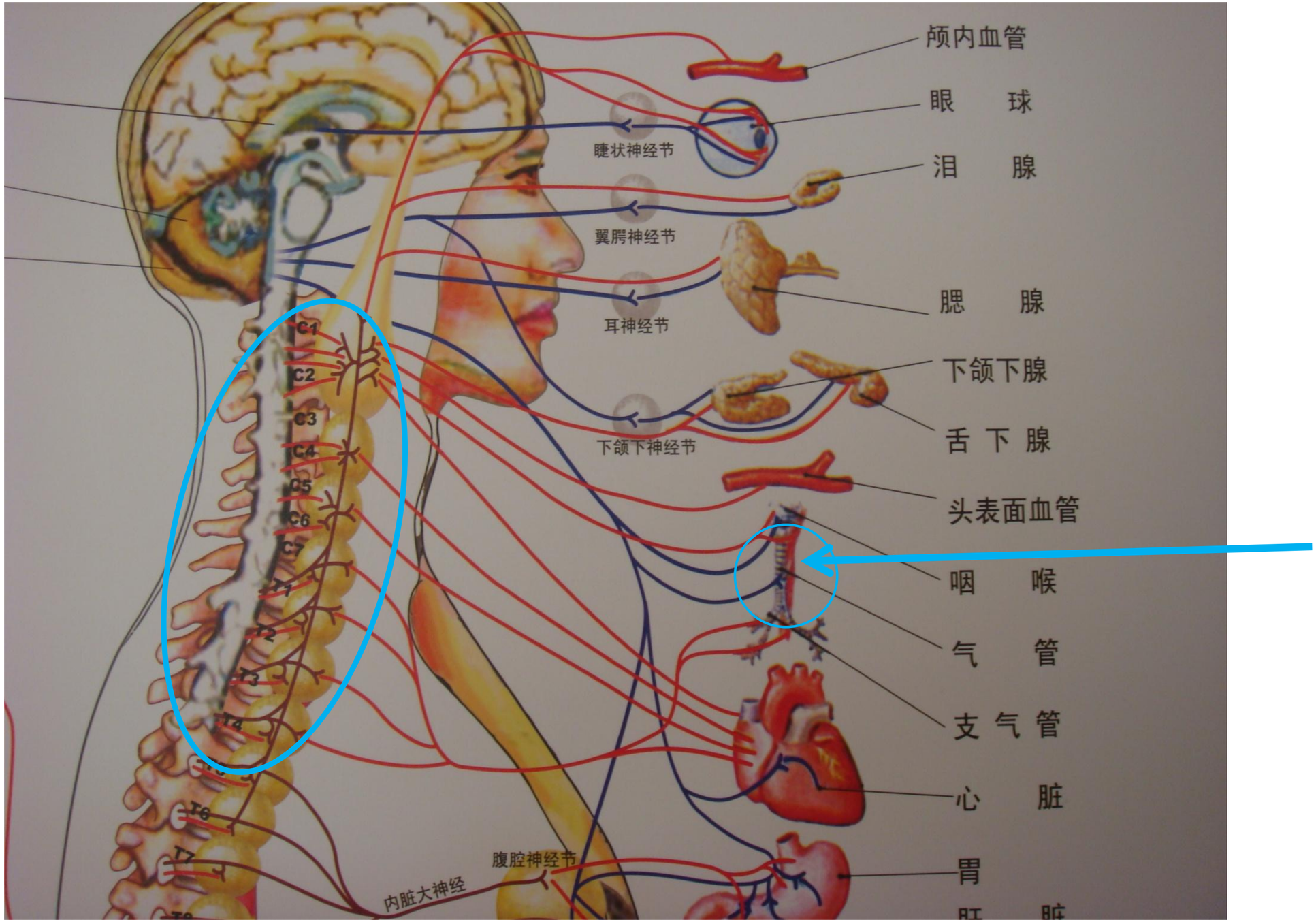
颅内血管
眼　球
泪　腺
睫状神经节
翼腭神经节
胰　腺
耳神经节
下颌下腺
舌 下 腺
下颌下神经节
头表面血管
咽　喉
气　管
支 气 管
心　脏
胃
腹腔神经节
内脏大神经
C1
C2
C3
C4
C5
C6
C7
T1
T2
T3
T4
T6
T7

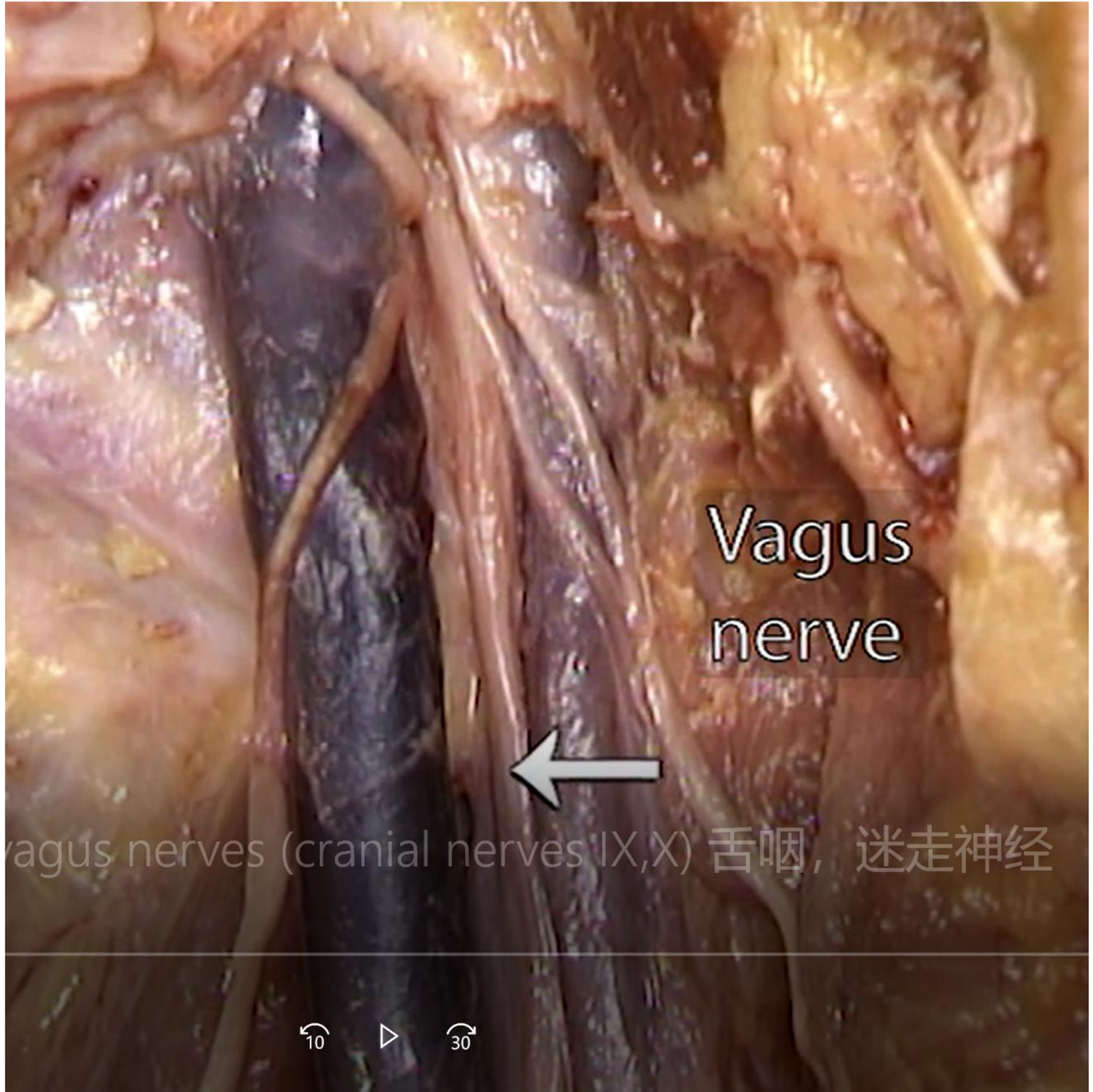

vagus nerves (cranial nerves IX,X) 舌咽，迷走神经

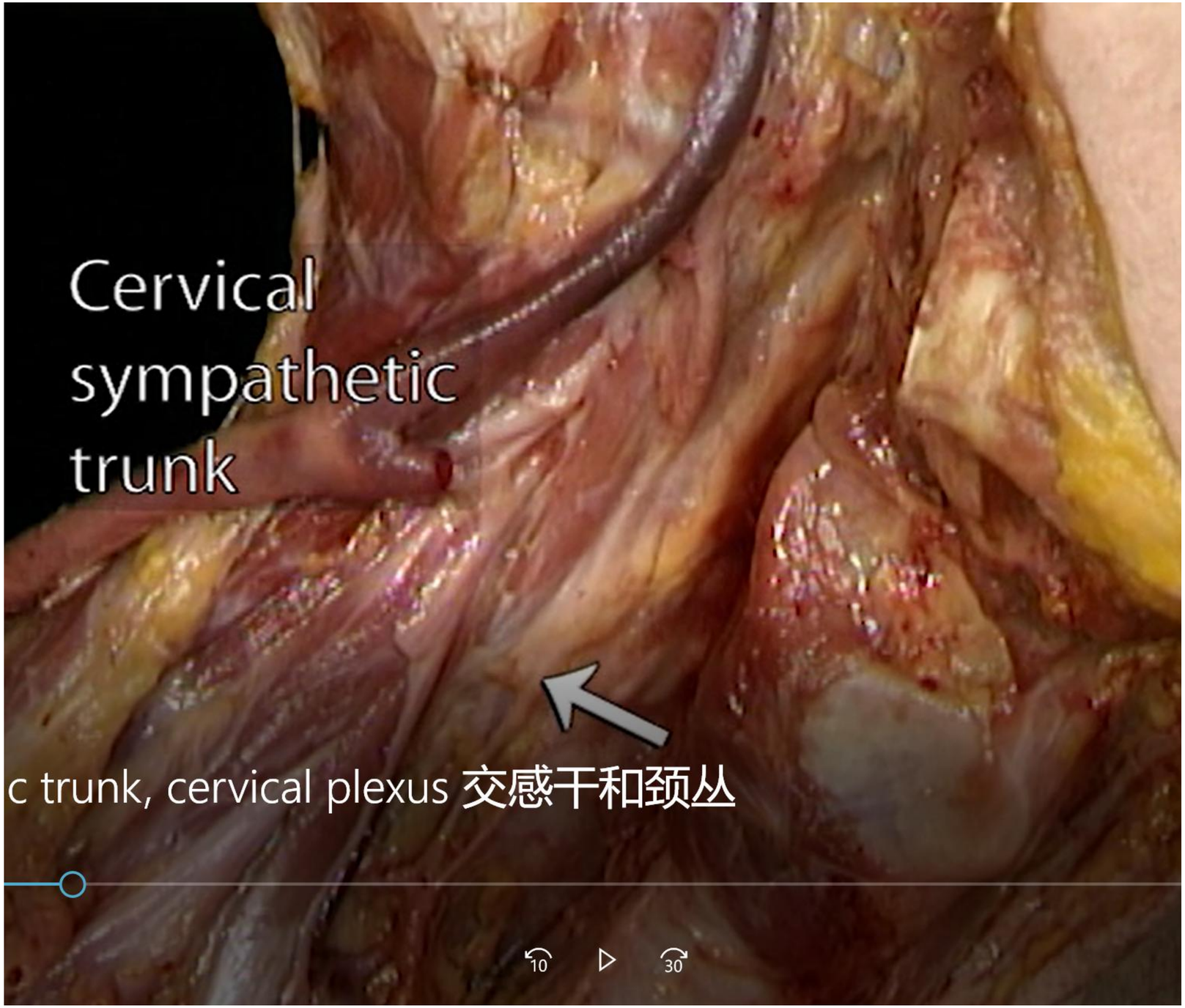
Cervical
sympathetic
trunk
c trunk, cervical plexus 交感干和颈丛
10
30

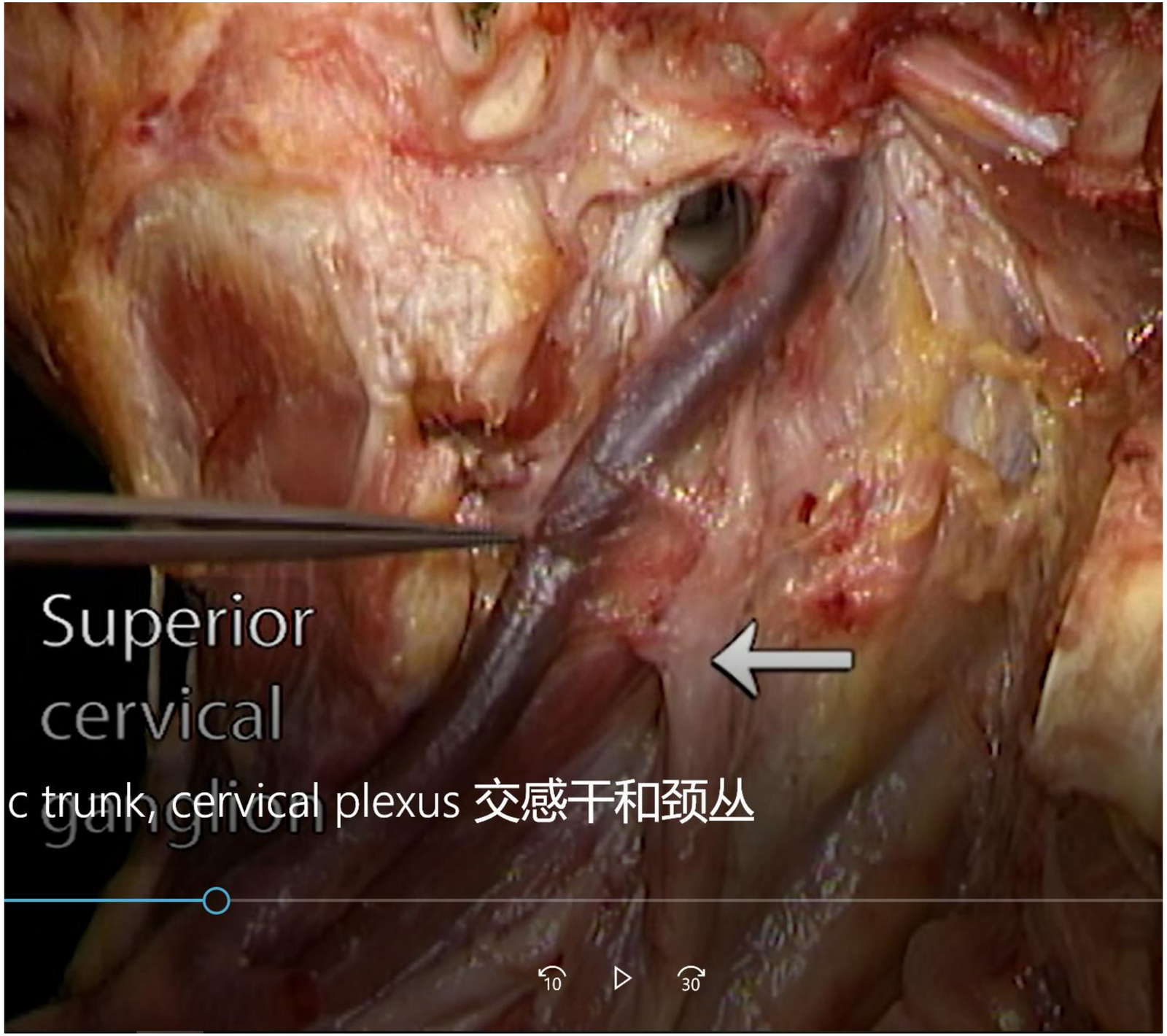

c trunk, cervical plexus 交感干和颈丛

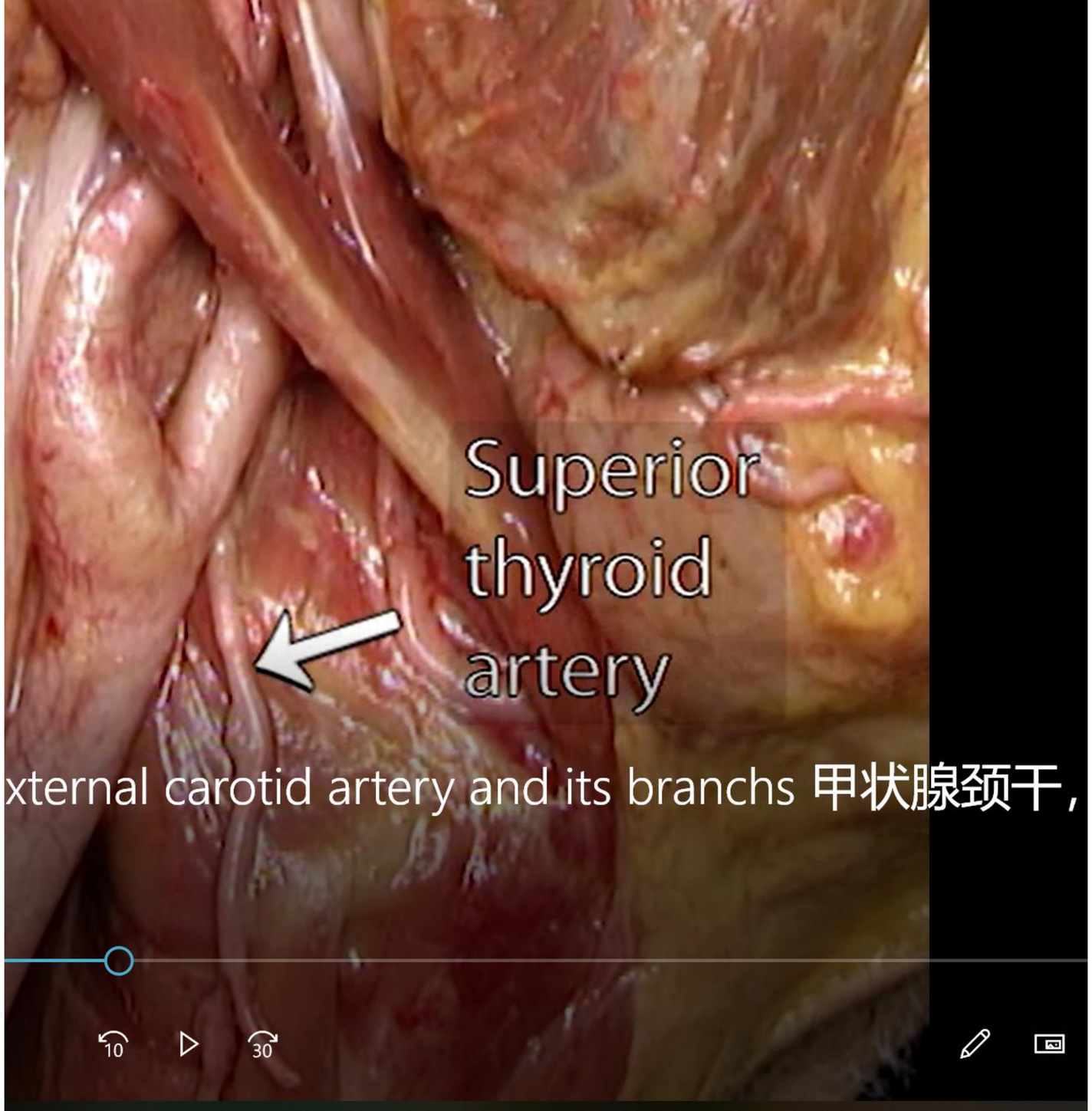

xternal carotid artery and its branchs 甲状腺颈干，

Cervical Sympathetic Trunk 颈交感神经干

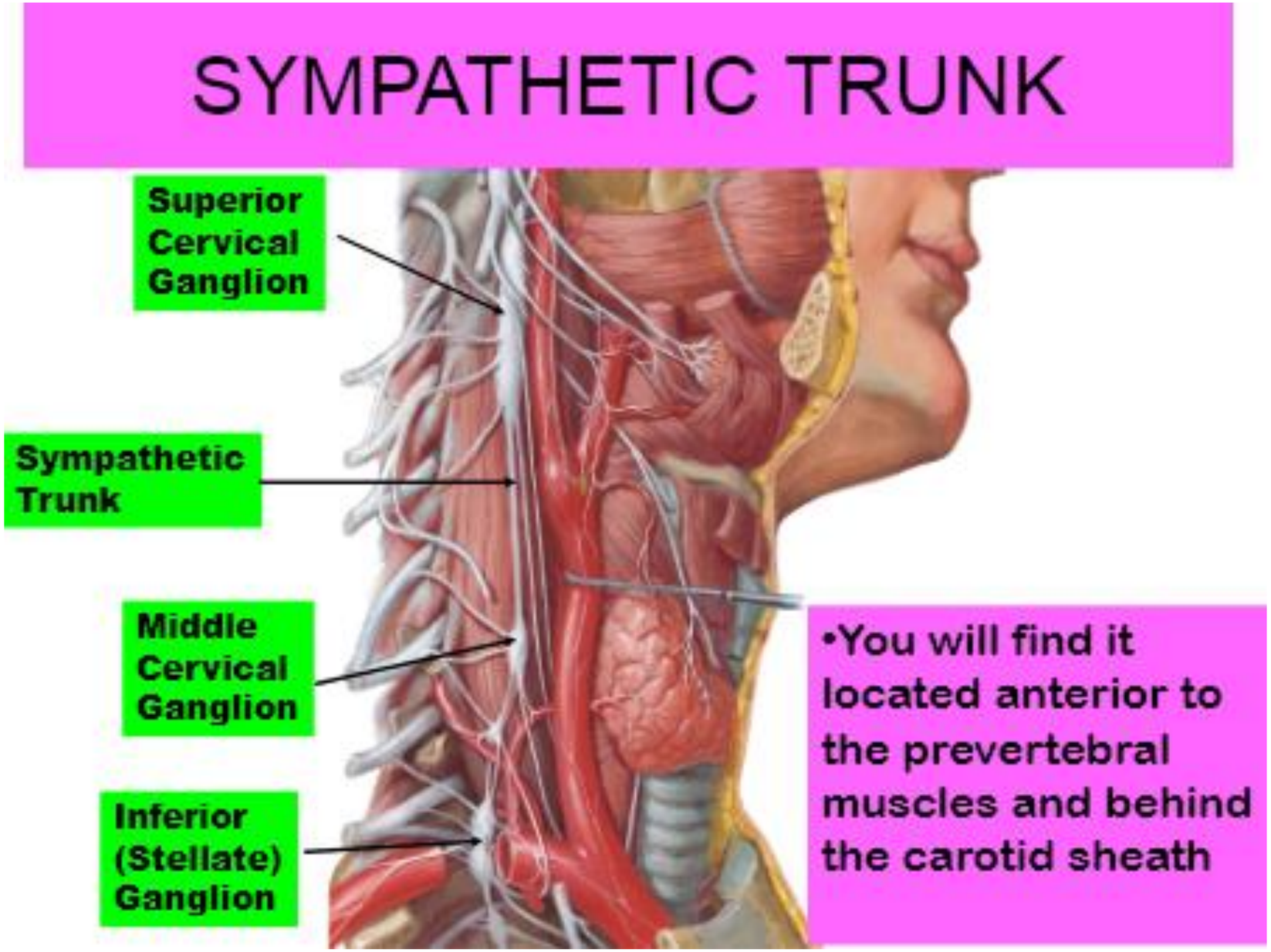

Cervical Sympathetic Trunk 颈交感神经干

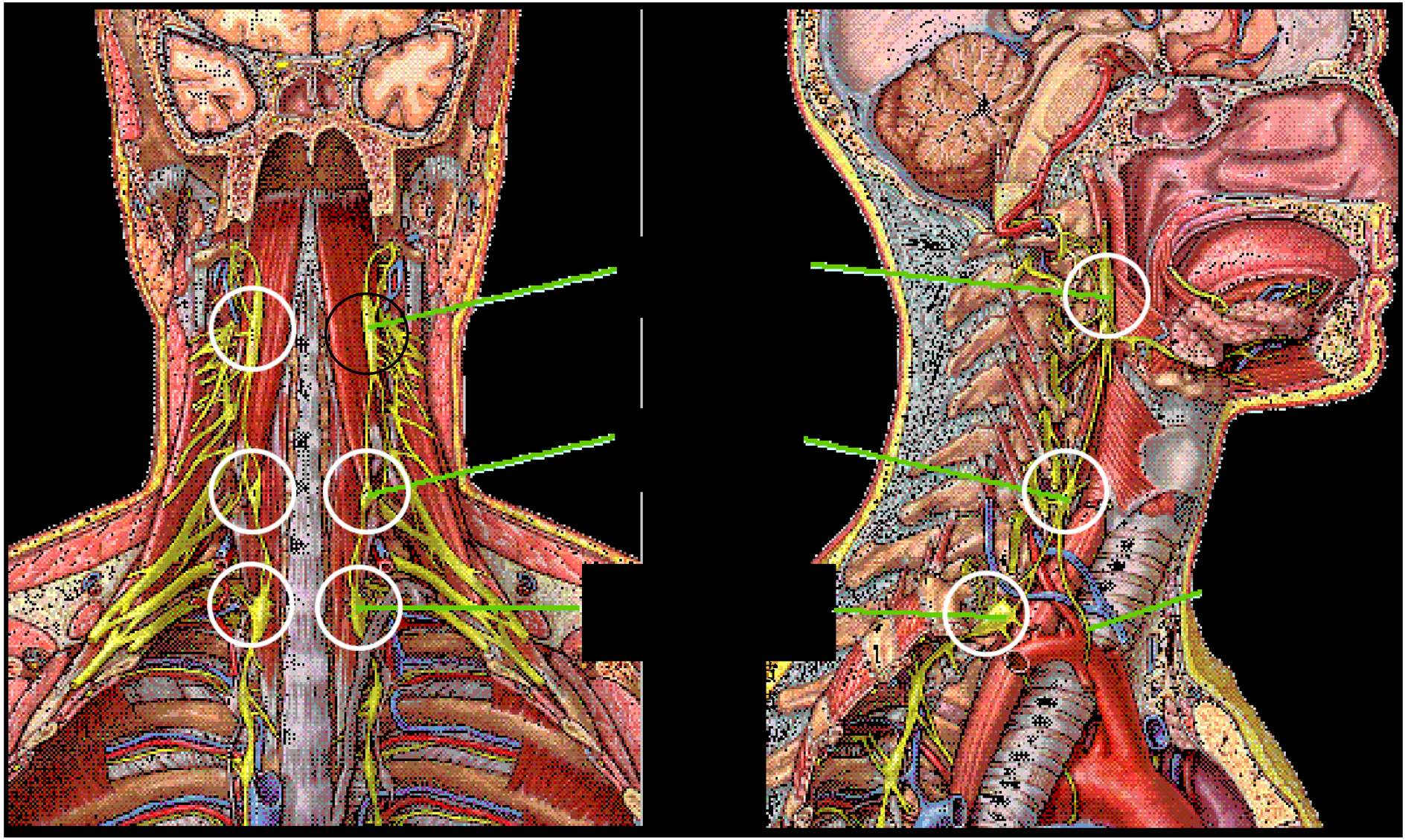

Locations 具体位置

Superior Ganglion
C1~C3 level 颈上神经节

Middle Ganglion
C5~C6 level 颈中神经节

Inferior / 颈下神经节
Cervicothoracic/颈胸神经节
Stellate Ganglion 星状神经节
C7~T1 level

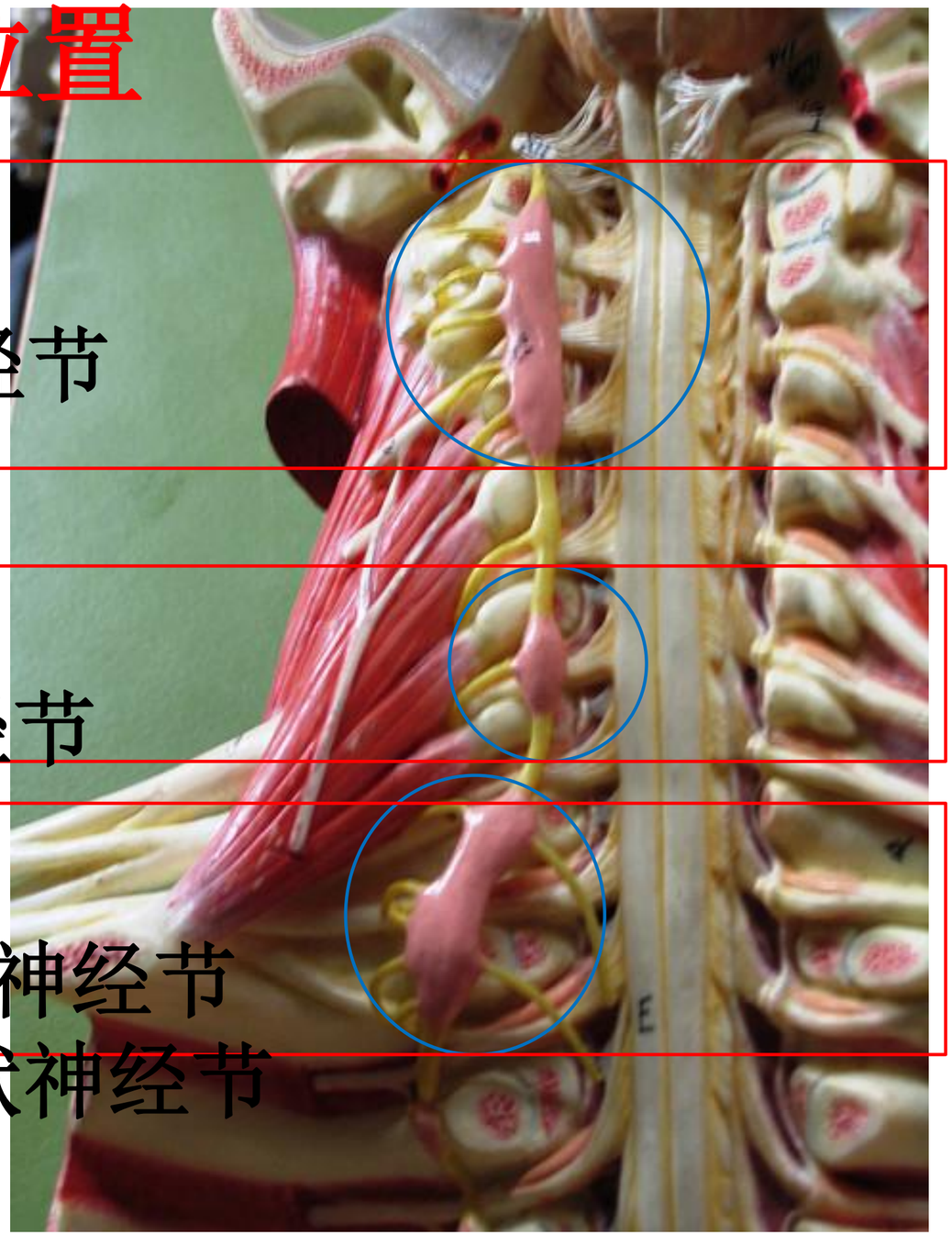

Cervical Sympathetic Ganglion (superior, meddle, inferior)
颈部上、中、下交感N节

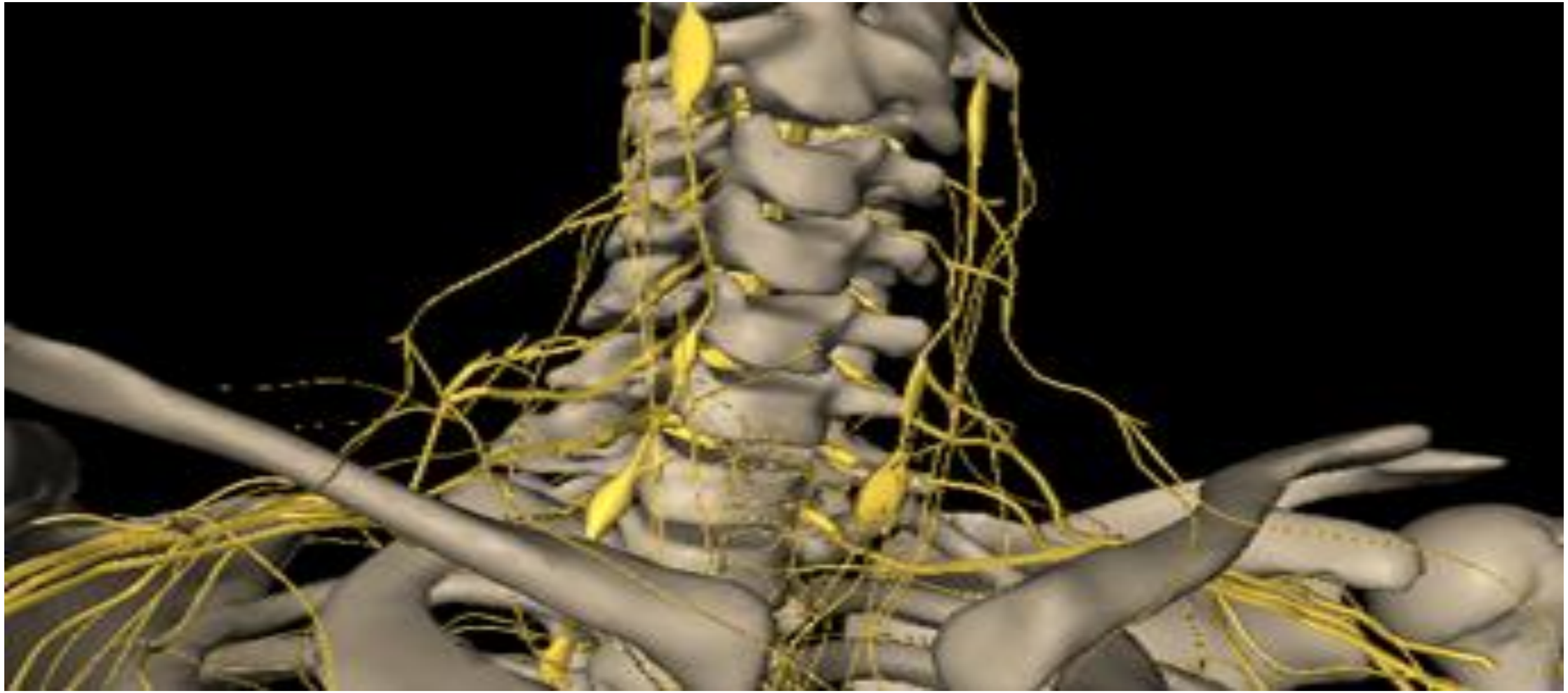

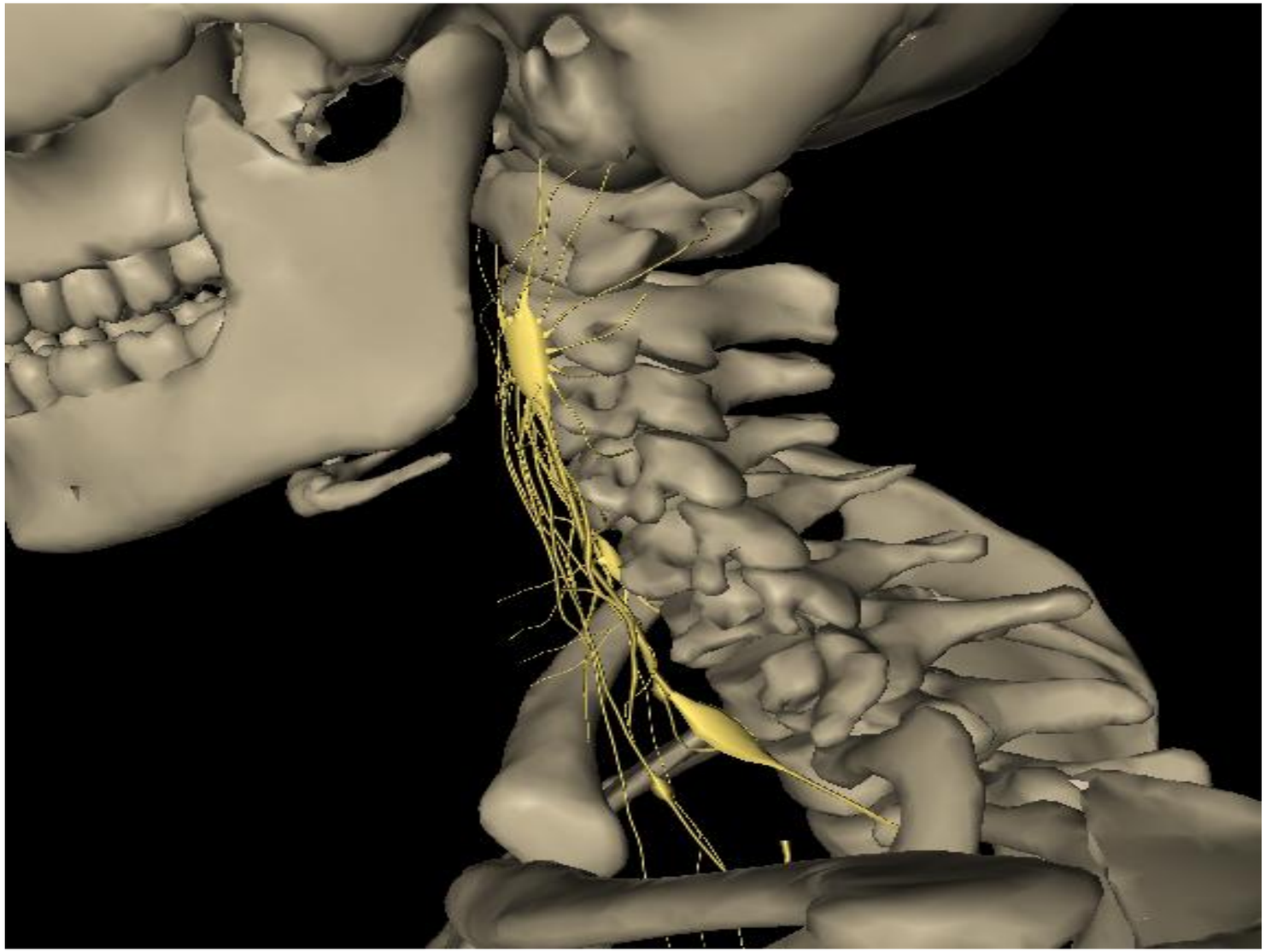

1. Superior Cervical Sympathetic Ganglion

The superior cervical sympathetic ganglion is the largest of the 3 ganglias in the neck.

1.颈上神经节

颈上神经节是颈部3个神经节中最大的一个.

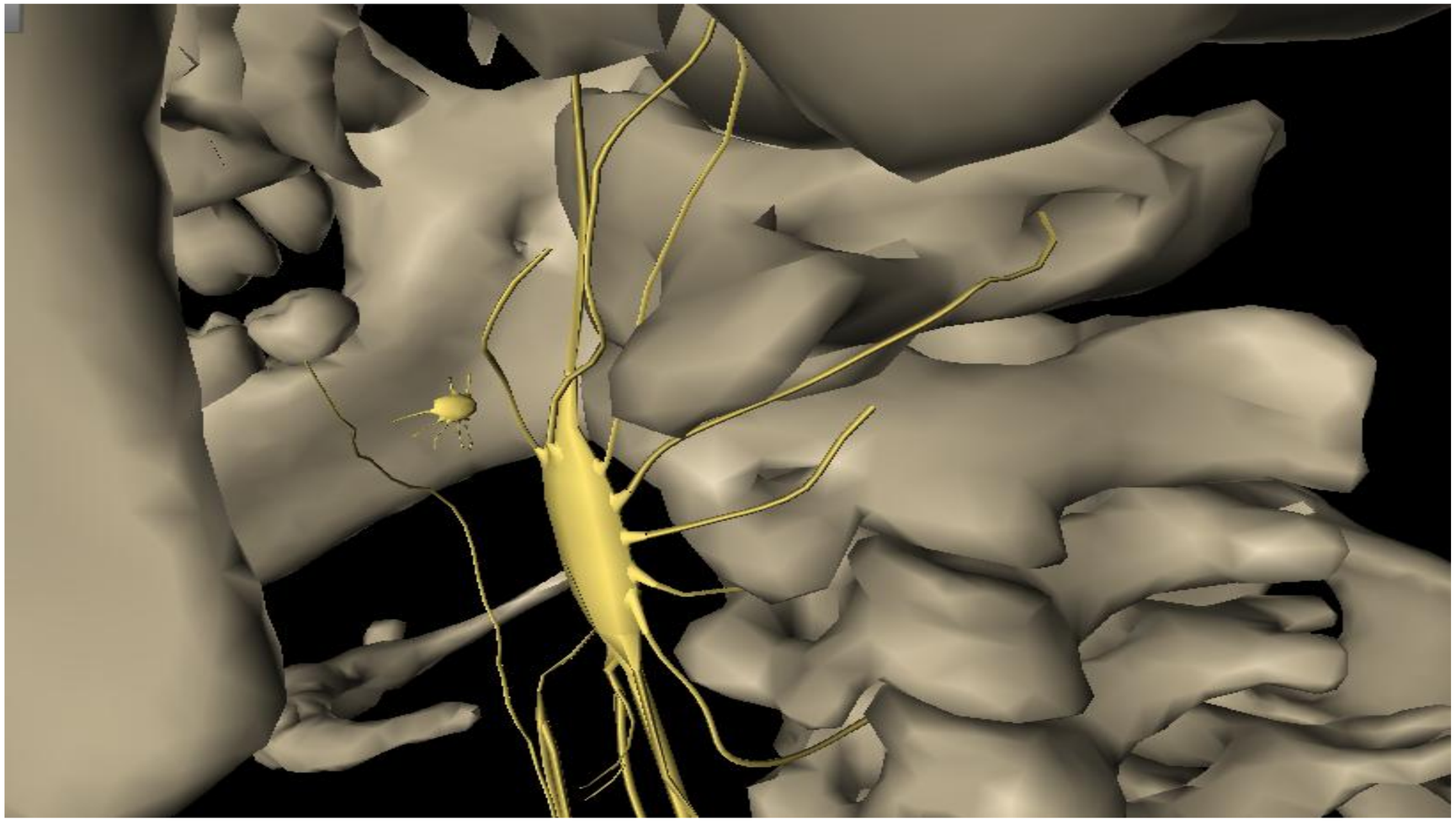

Superior cervical sympathetic Ganglion:

- Length: 20 to 50 mm, central width: 7.9 mm, thickness: 3.2 mm, 88% are seam-shaped, 10% are circular, and 2% are kidney-shaped.
- It is located anterior to the transverse process of C1 to C4, and 15 mm inferoposterior to the sternocleidomastoid muscle.
- 79% of the nodes connect to the transverse process of C1
- 51% connect to the transverse process of C3.
- The superior cervical ganglion communicates with the carotid plexus, internal carotid plexus, external carotid plexus, cervical artery plexus, pharyngeal plexus, ocular plexus, superior cardiac plexus, etc.

长20一50mm，中间宽7.9mm，厚3.2mm。呈纺锤形占88%，圆形10%，肾形2%
位于CI一C4横突前方，胸索乳突肌乳突端后下方15mm
节的上端对C1横突者79%，下端有51%对C3横突
颈上神经节主要发生颈总动脉丛、颈内动脉丛、颈外动脉丛、椎动脉丛、咽候支、眼支、心上支等

2. Carotid sinus

颈动脉窦压力感受器变化

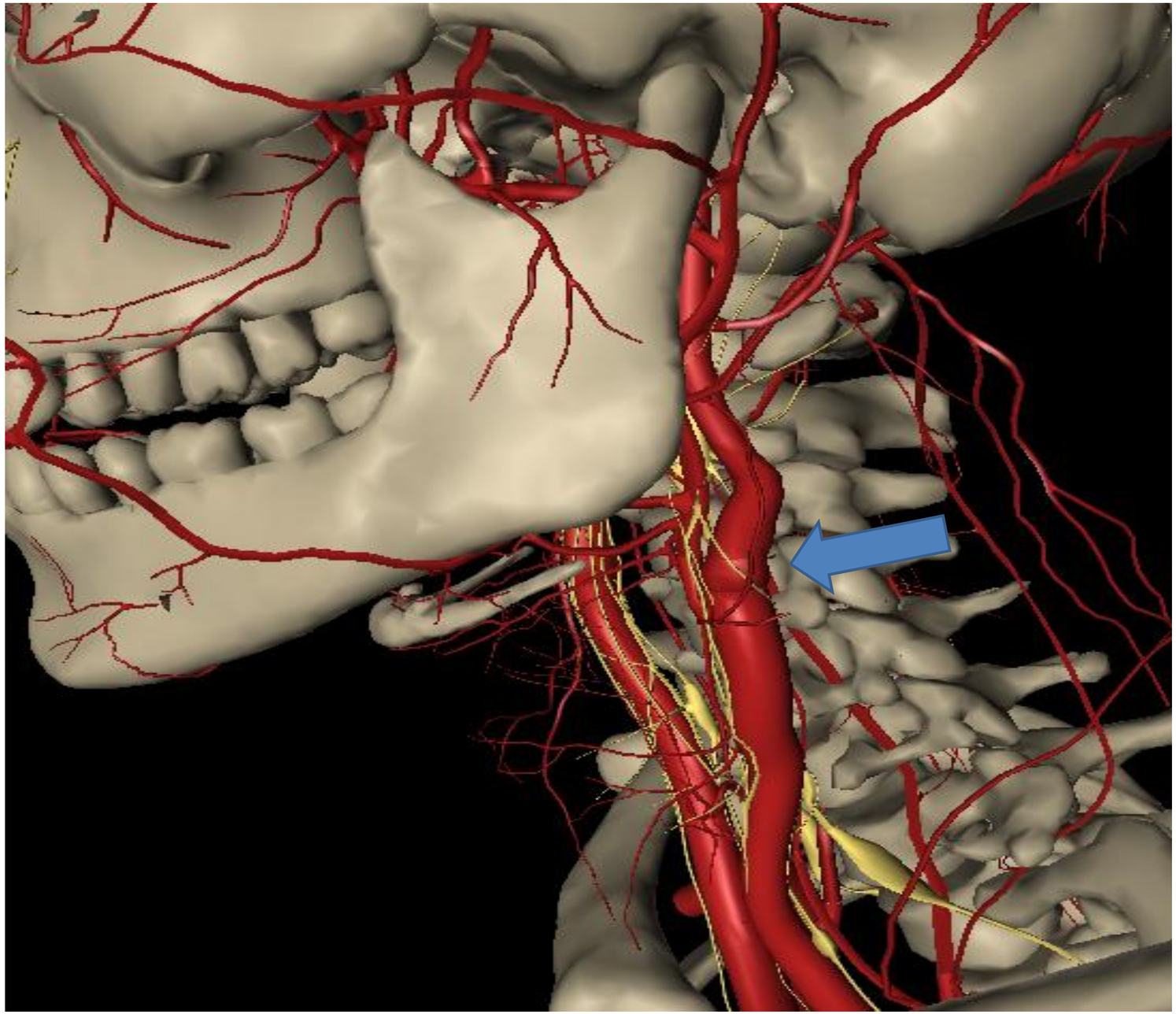

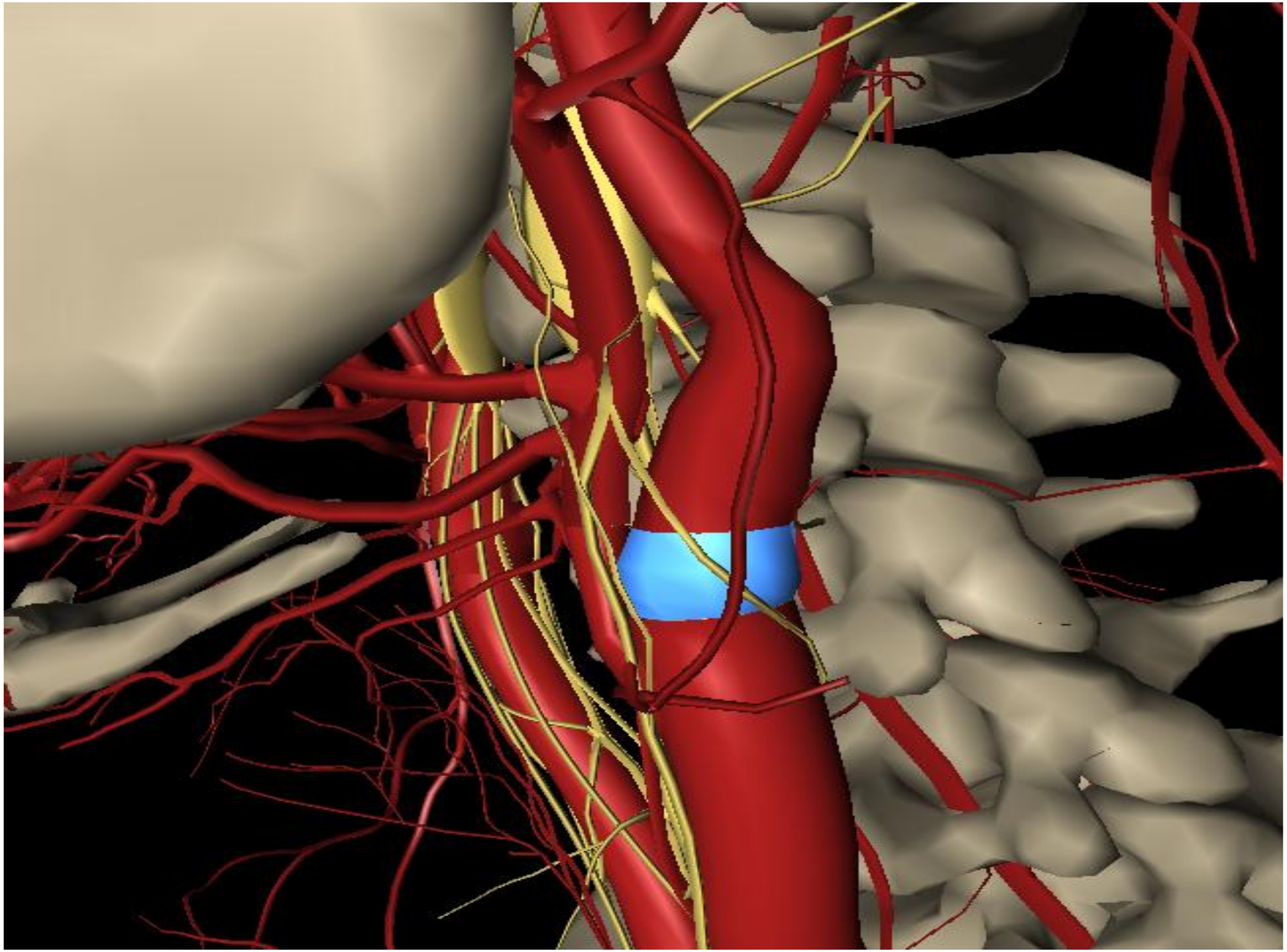

- Carotid sinus is located at the division of the common carotid artery with the internal and external carotid artery.

位于颈总动脉与颈内、外动脉的分叉处

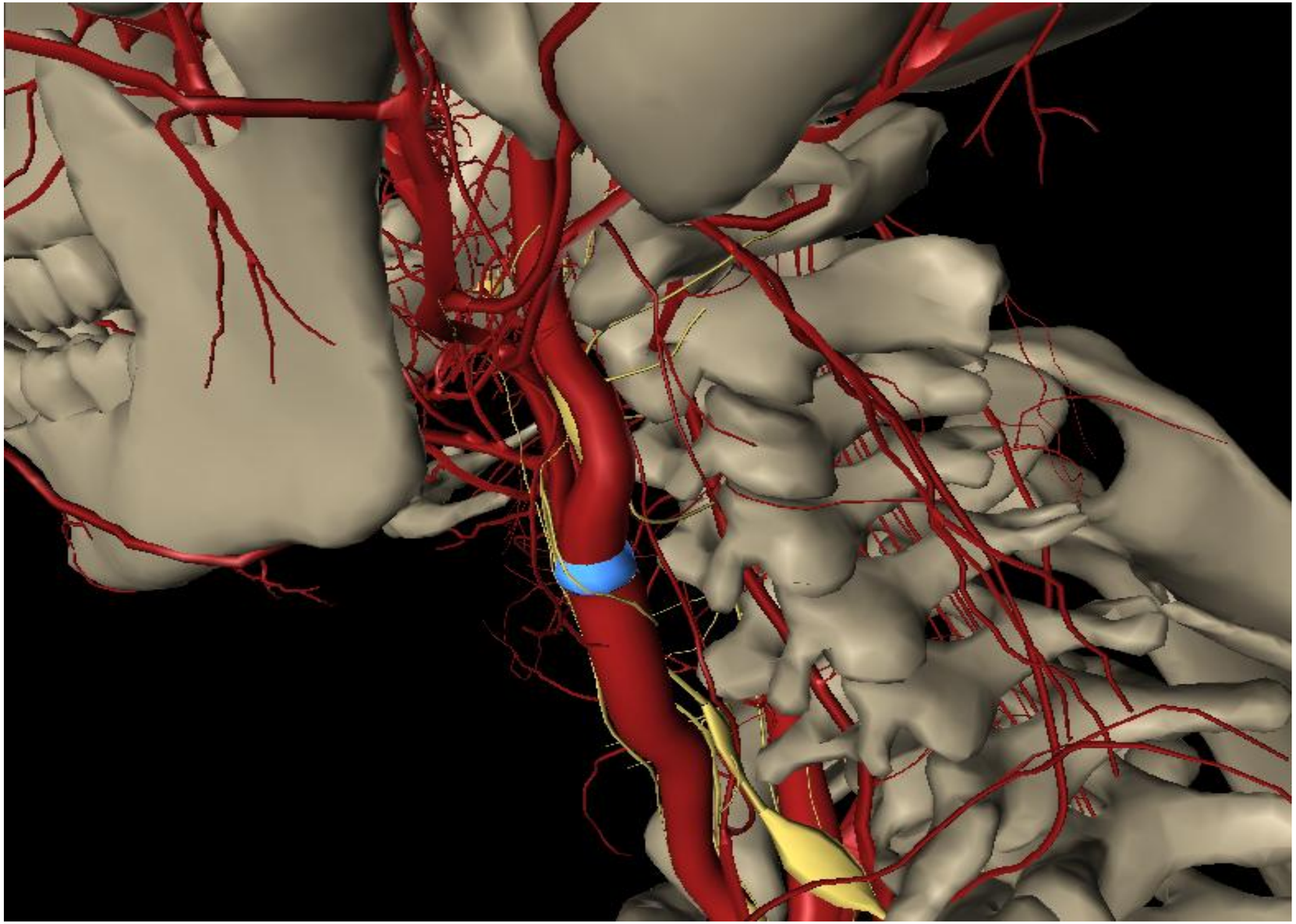

- The carotid sinus is located on the anterolateral aspect of the transverse process of C4.
- In the flexion position, the carotid sinus, along with the muscles at the level of C5 to C6, moves along the anterolateral aspect of these transverse processes.

在C4横突前外侧(此为仰卧位尸解定位)，当低头伏案，隨颈前肌群收缩而使颈动脉窦下移，多位于C5一C6颈椎横突前外侧。

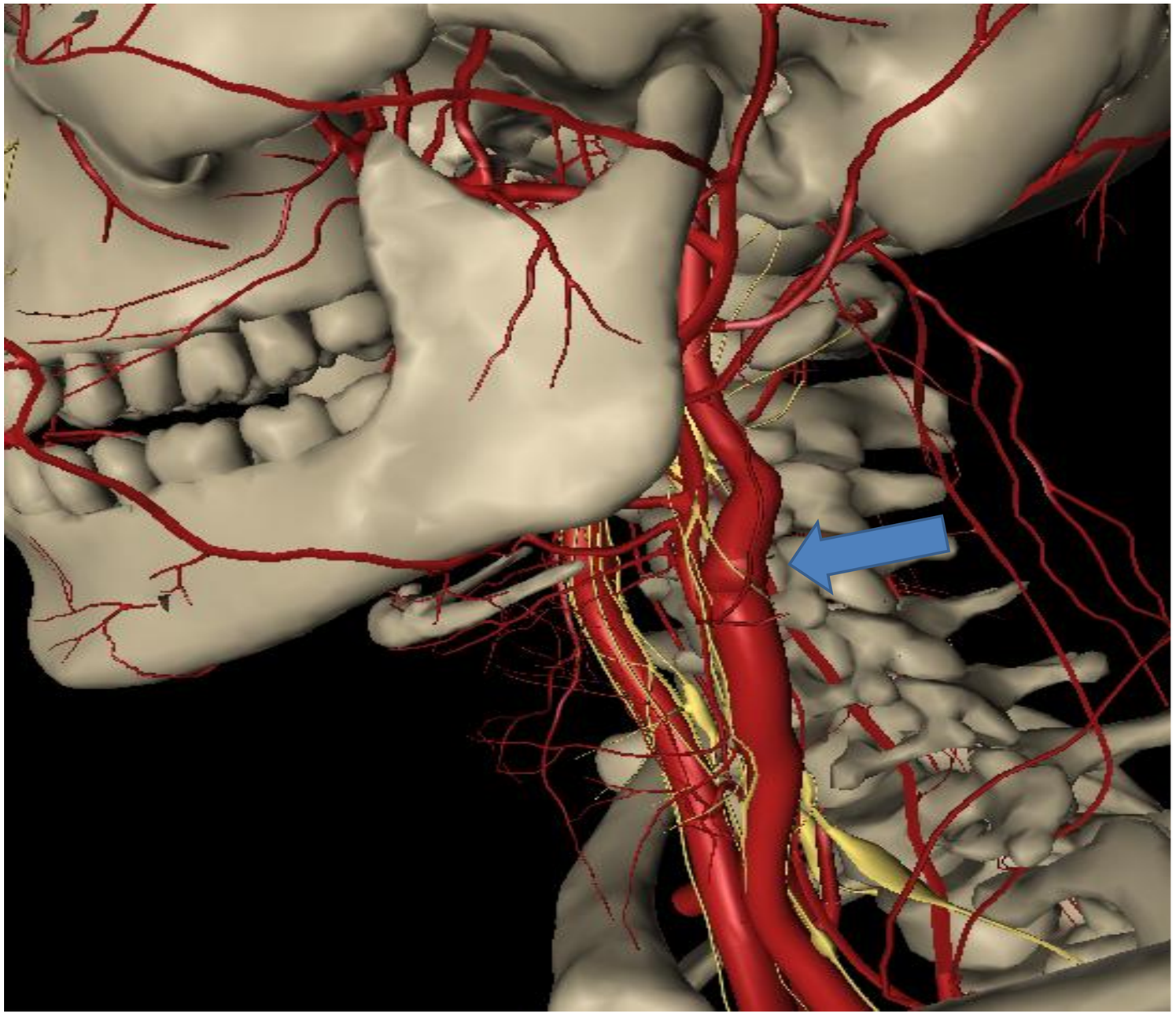

- Vulnerable to injury to the carotid sinus due to constant head movement, which irritates and inhibits the carotid sinus receptor, causing hypertension.

当头部经常运动，损伤了颈动脉窦周围筋膜，刺激颈动脉窦压力感受器，导致降压功能下降，使血压维持在较高水平

3. Changes around the upper thoracic sympathetic nerve trunk

- The preganglionic fibers of the upper thoracic sympathetic nerve reach the upper, middle, and lower cervical sympathetic nerves, and then the postganglionic fibers are sent out from the sympathetic nerves.
- Vertebral dislocation in the upper thoracic segment can stimulate the sympathetic nerves.

3.上胸段交感N干周围变化

上胸段交感N节前纤维到达颈上、中、下交感N节，再由交感N节发出节后纤维。上胸段的椎体错位可刺激交感N。

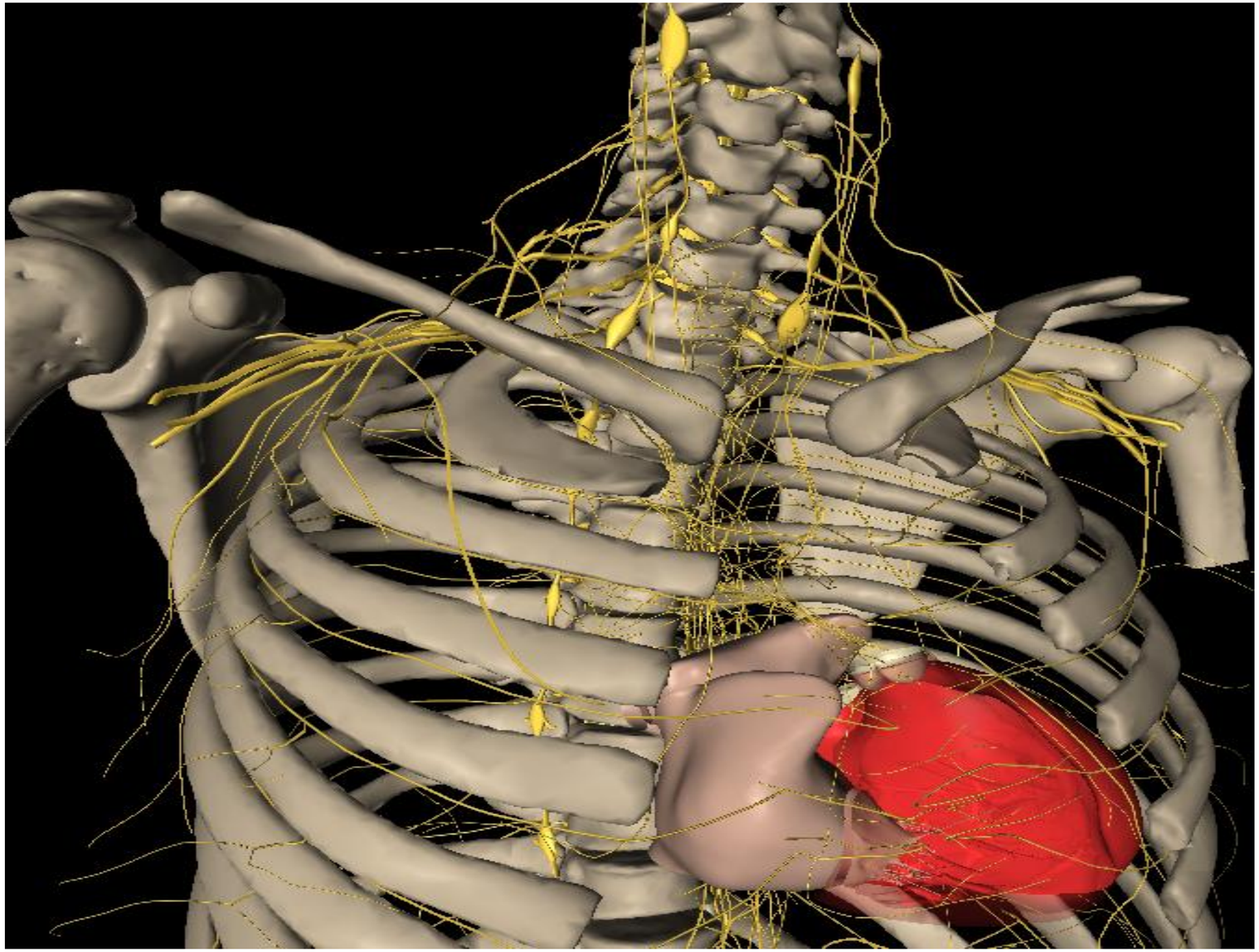

SJ17 Yifeng area, pass 8 nerves:

1. Vagus Nervous
2. Sympathetic Nervous
3. Parasympathetic Nervous
4. Facial Nervous
5. Trigeminal Nervous
6. Auditory Nervous
7. Hypoglossal Nervous
8. Phrenic Nervous

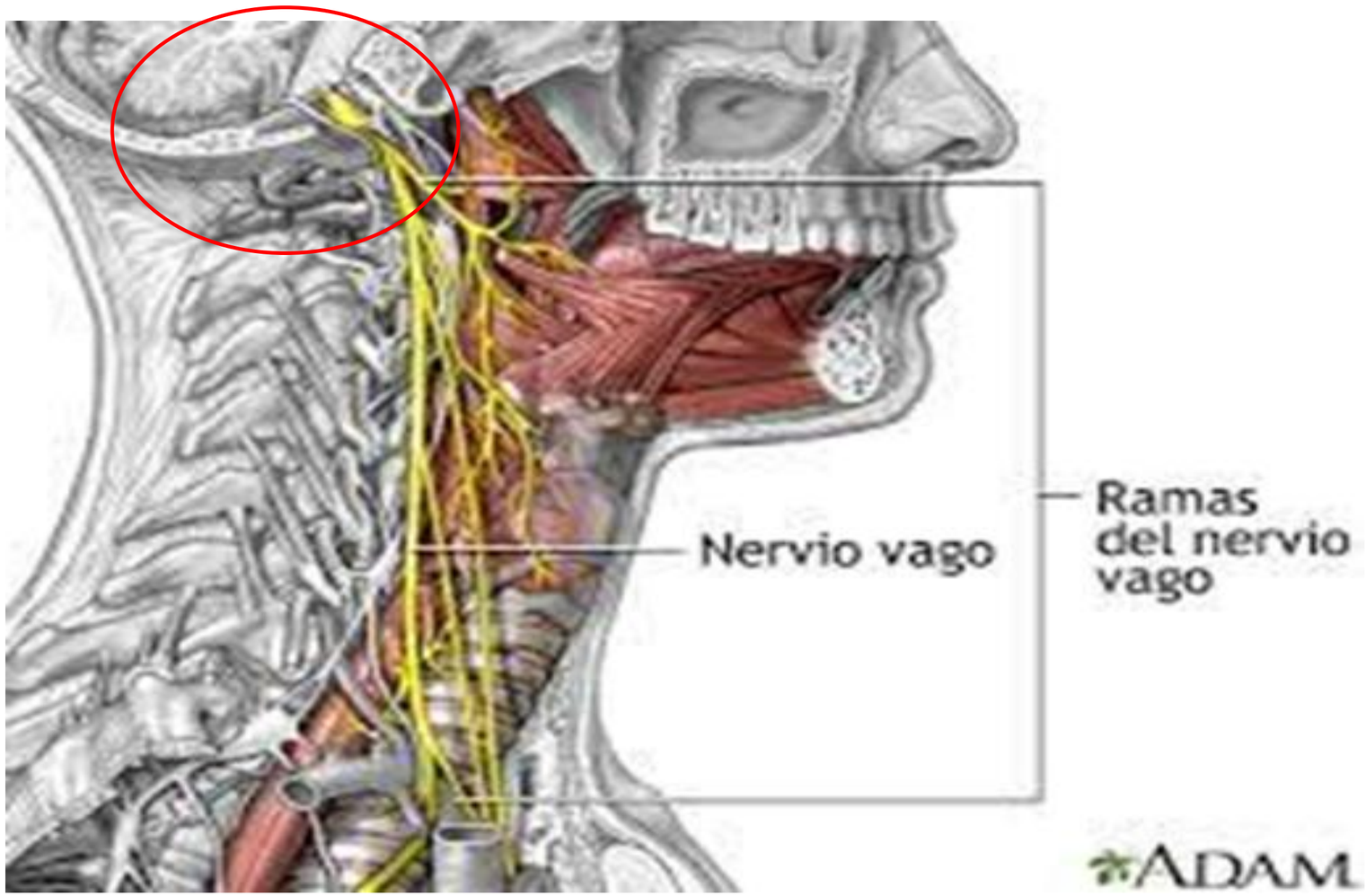

Stellate Ganglion 星状神经节

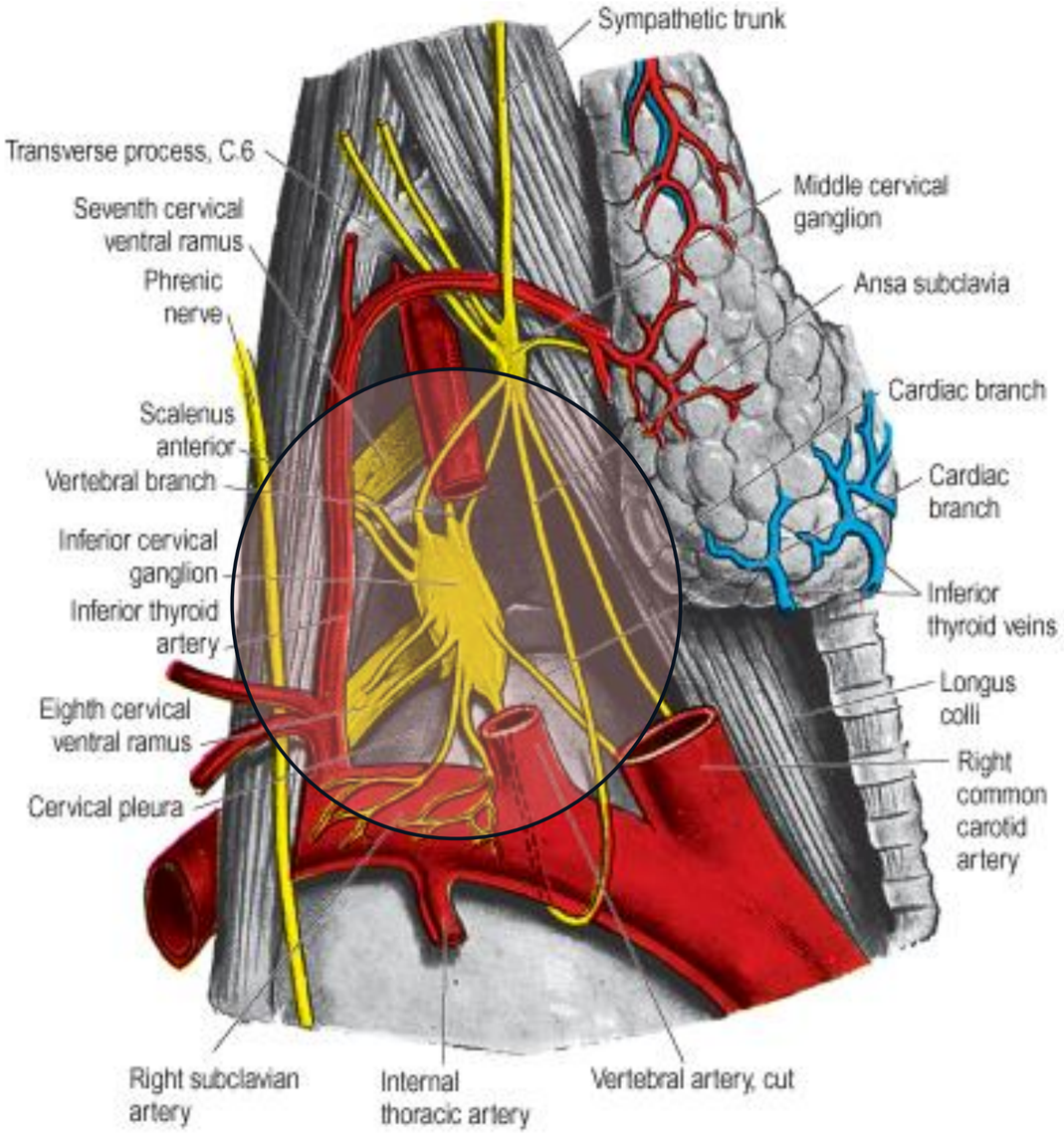

- Autonomic nervous system
- Endocrine system
- Immune system

- 植物神经系统
- 内分泌系统
- 免疫系统

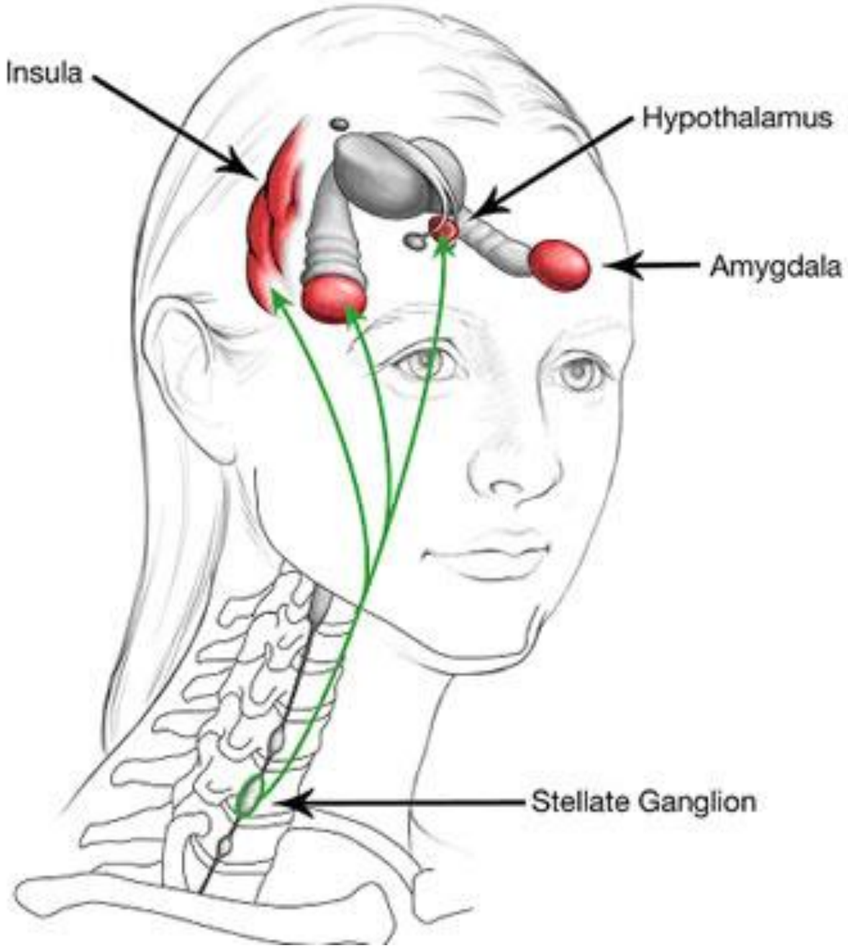

- Autonomic nervous system
- Endocrine system
- Immune system

- 植物神经系统
- 内分泌系统
- 免疫系统

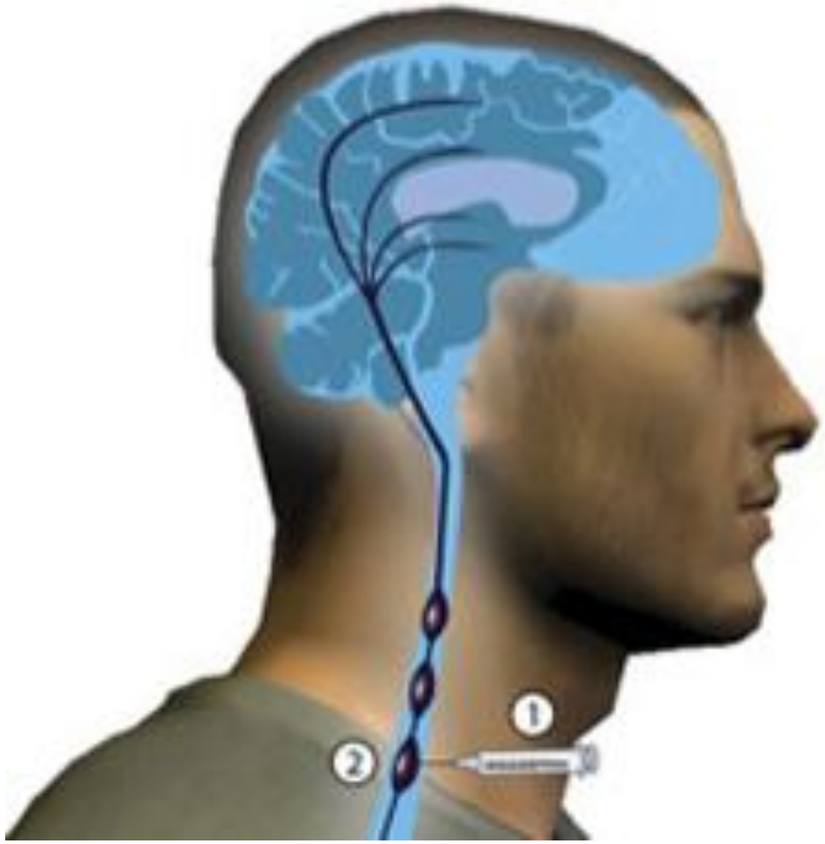

Location of Stellate Ganglion
星状神经节具体位置

Around C7~T1

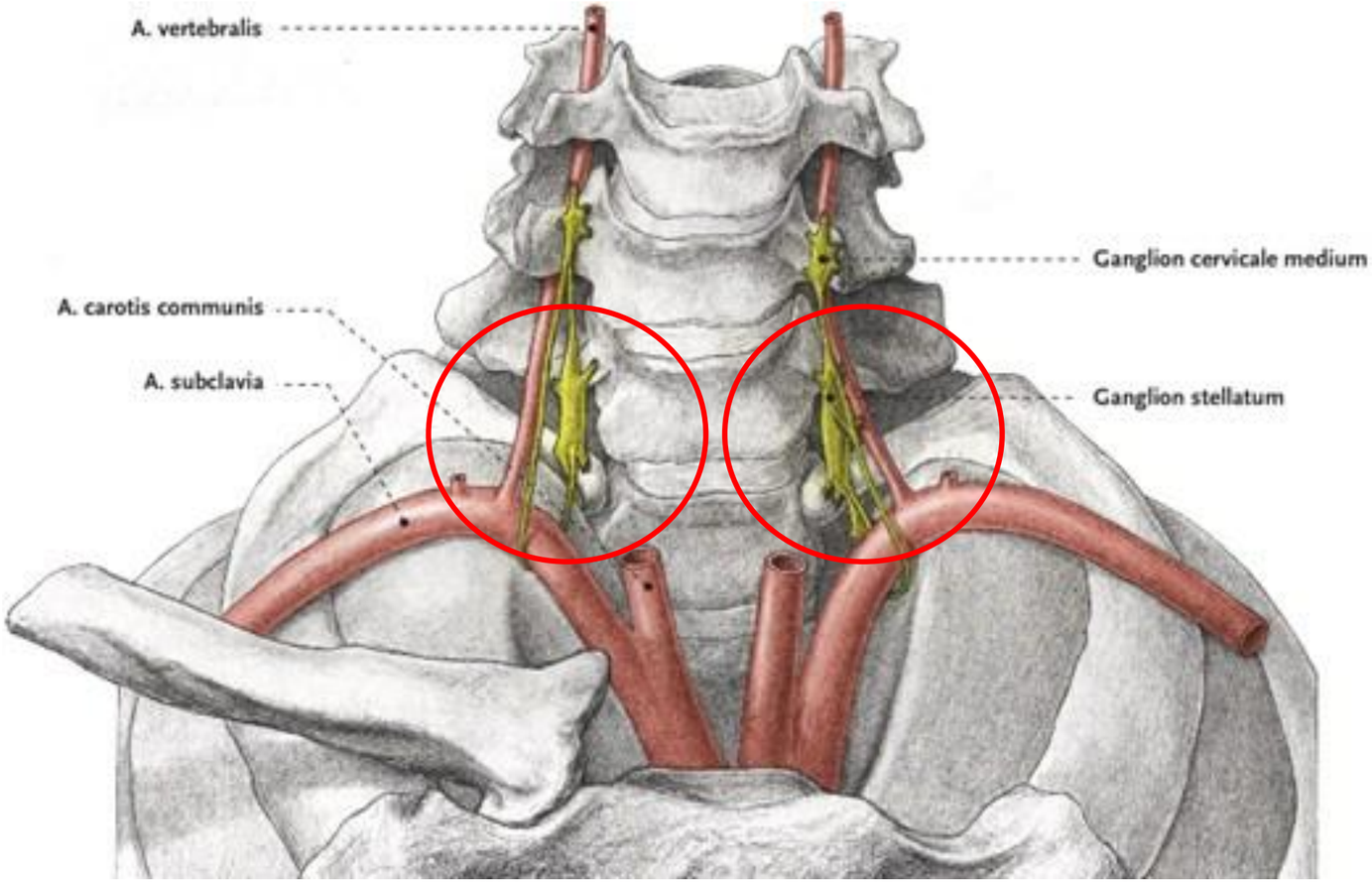

Stellate Ganglion Block Technique
星状神经节阻滞疗法

Stellate Ganglion Block Technique
星状神经节阻滞疗法

Pax. with Syndrome Hashimoto

Pax. with Hypertiroidism

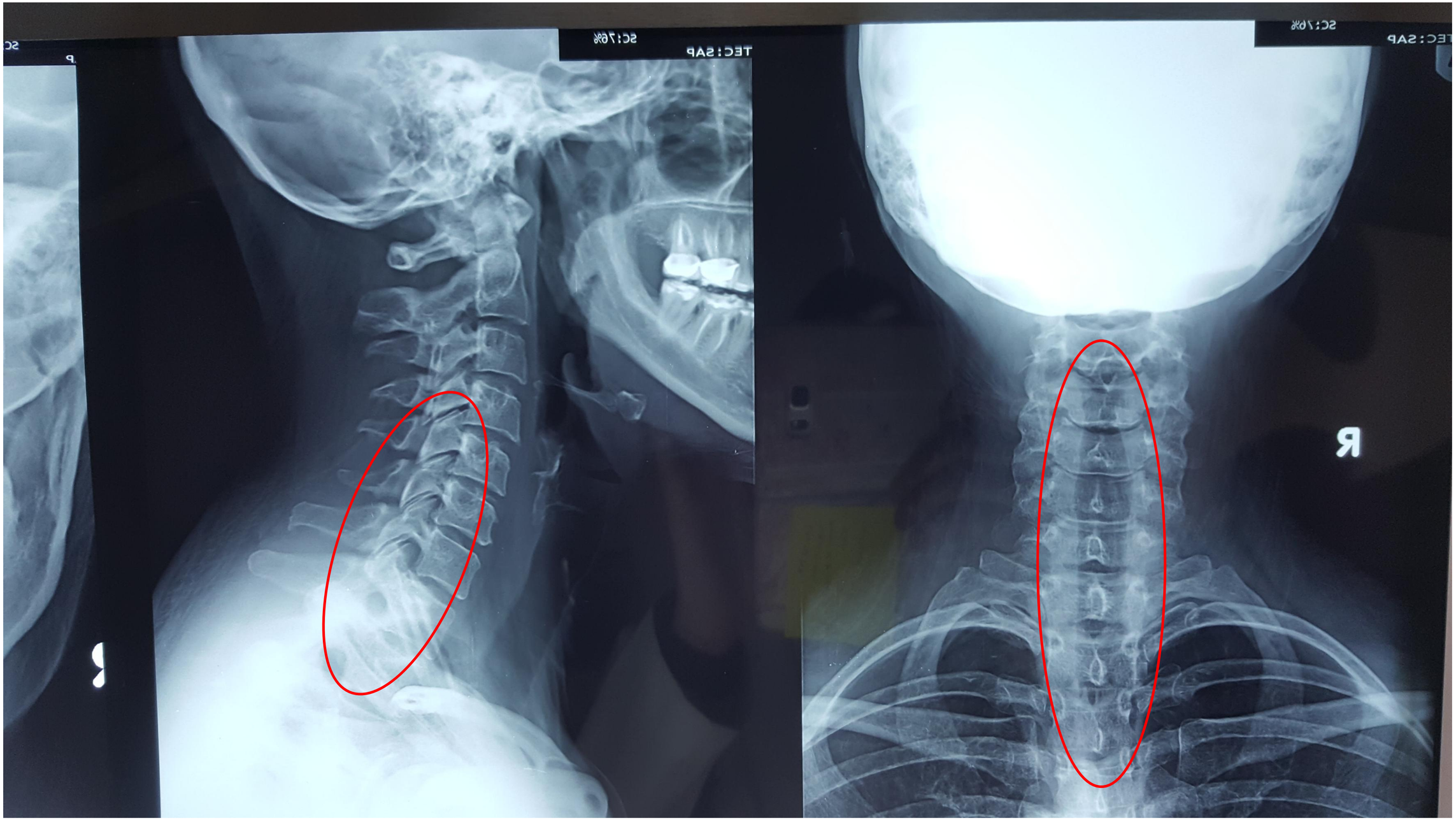

Pax. Thyroid cancer

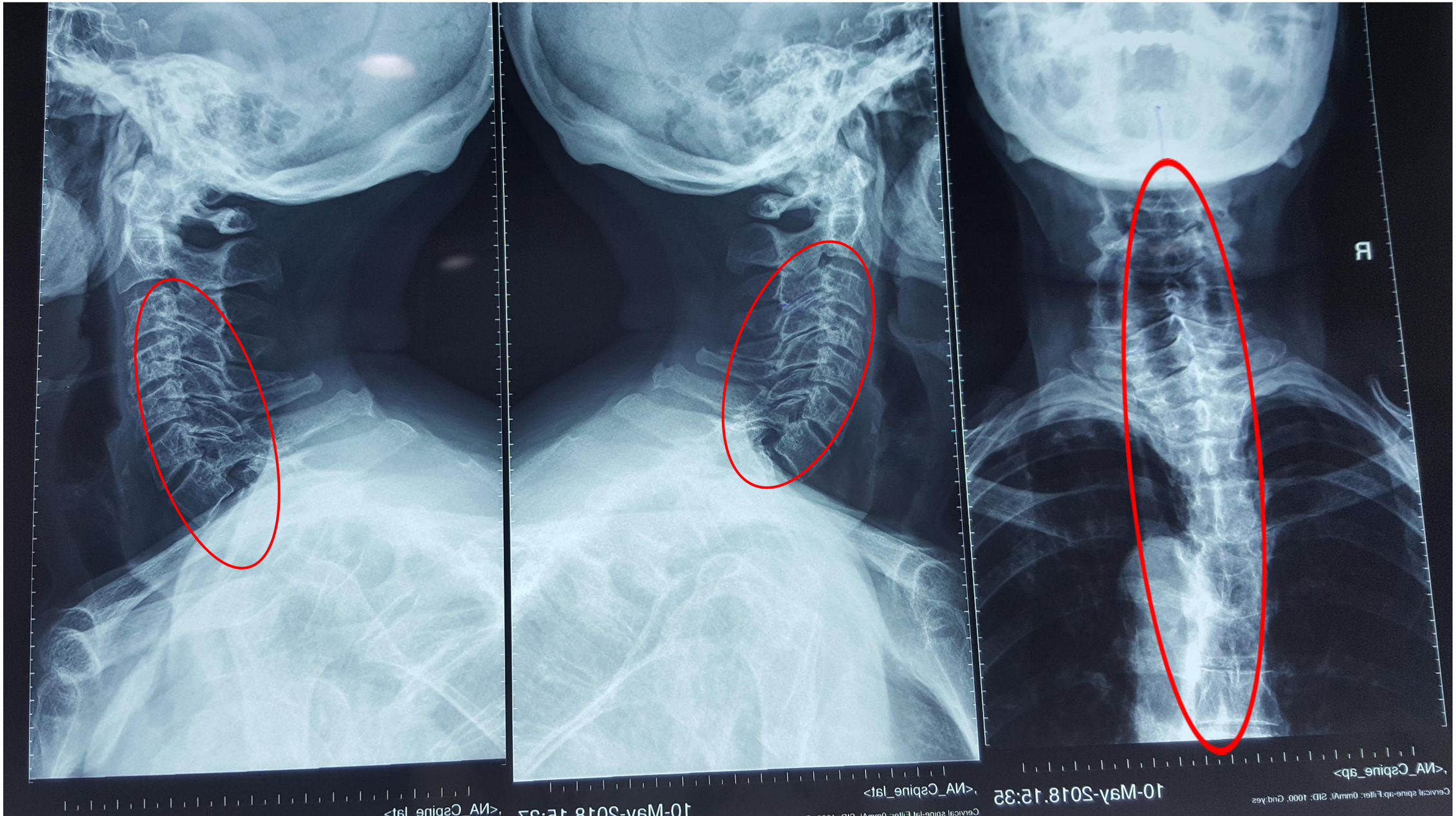


70 %
R
ap
.<NA Cspine_ap>
Cervical spine-ap.Filter: 0mmAl, SID: 1000, Grid:yes
AYALA LIDIA 86A.,*,Unknown,B09871
10-M

Severe vertebrae displacement

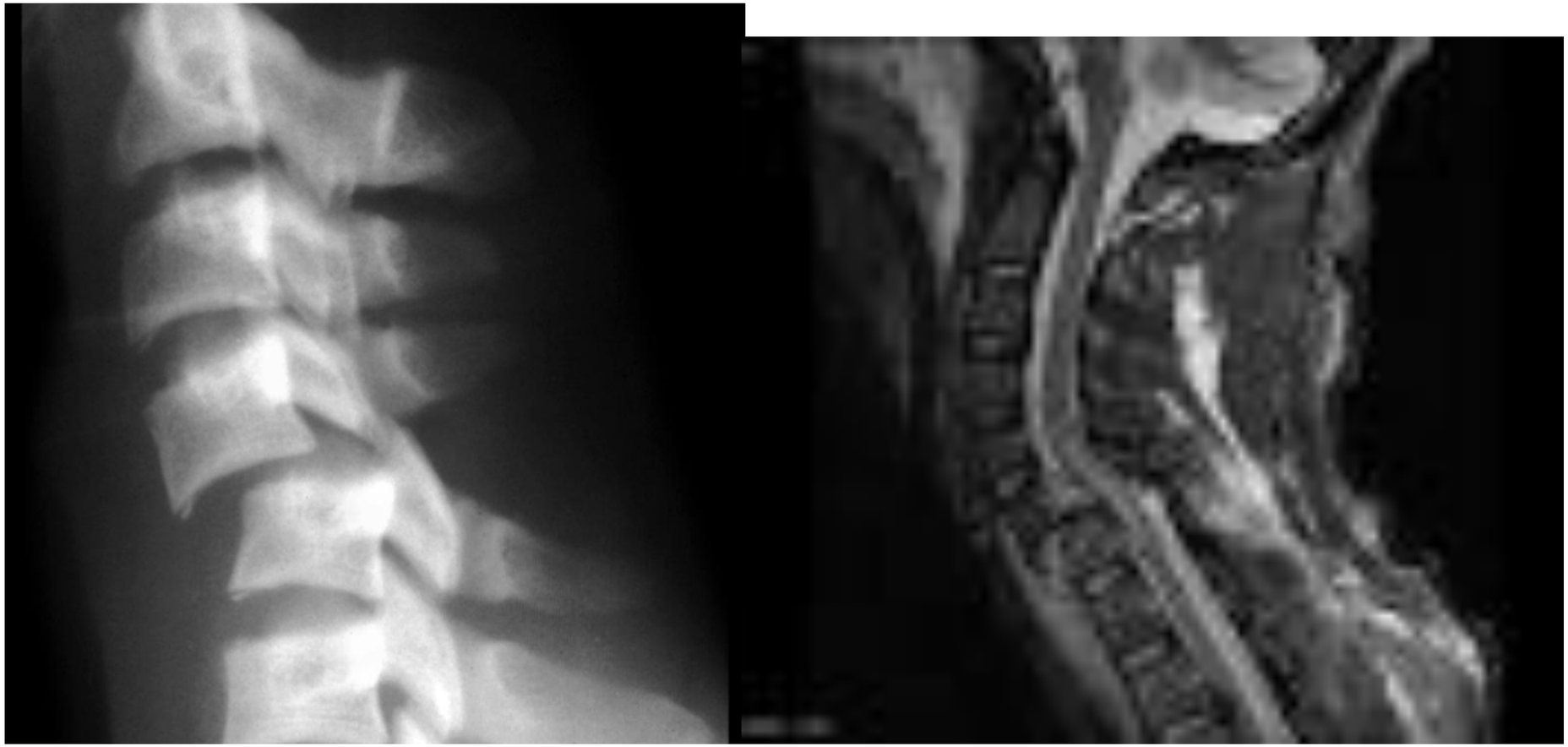

Scoliosis

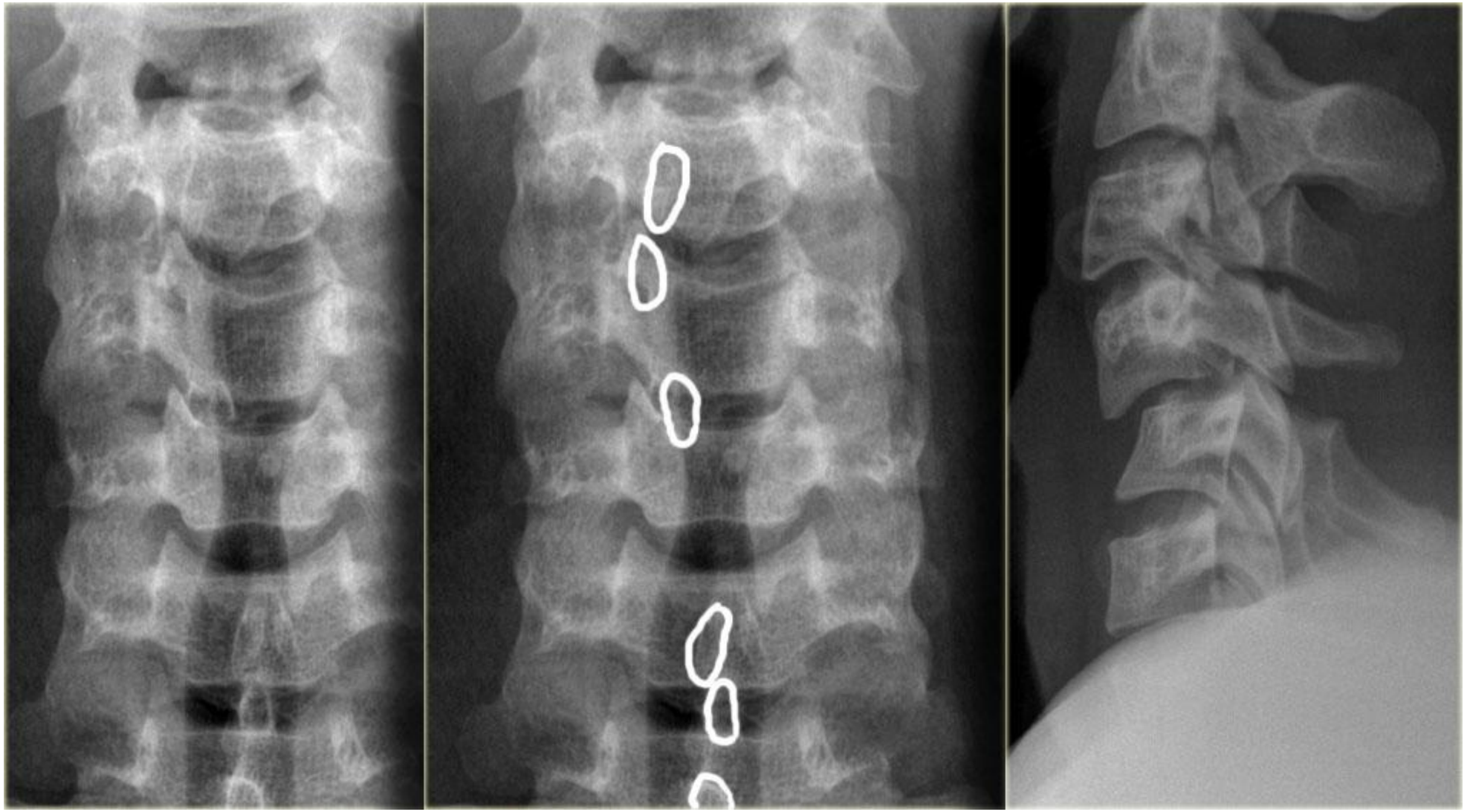

Foraminal stenosis

Cervical Rectification cervical

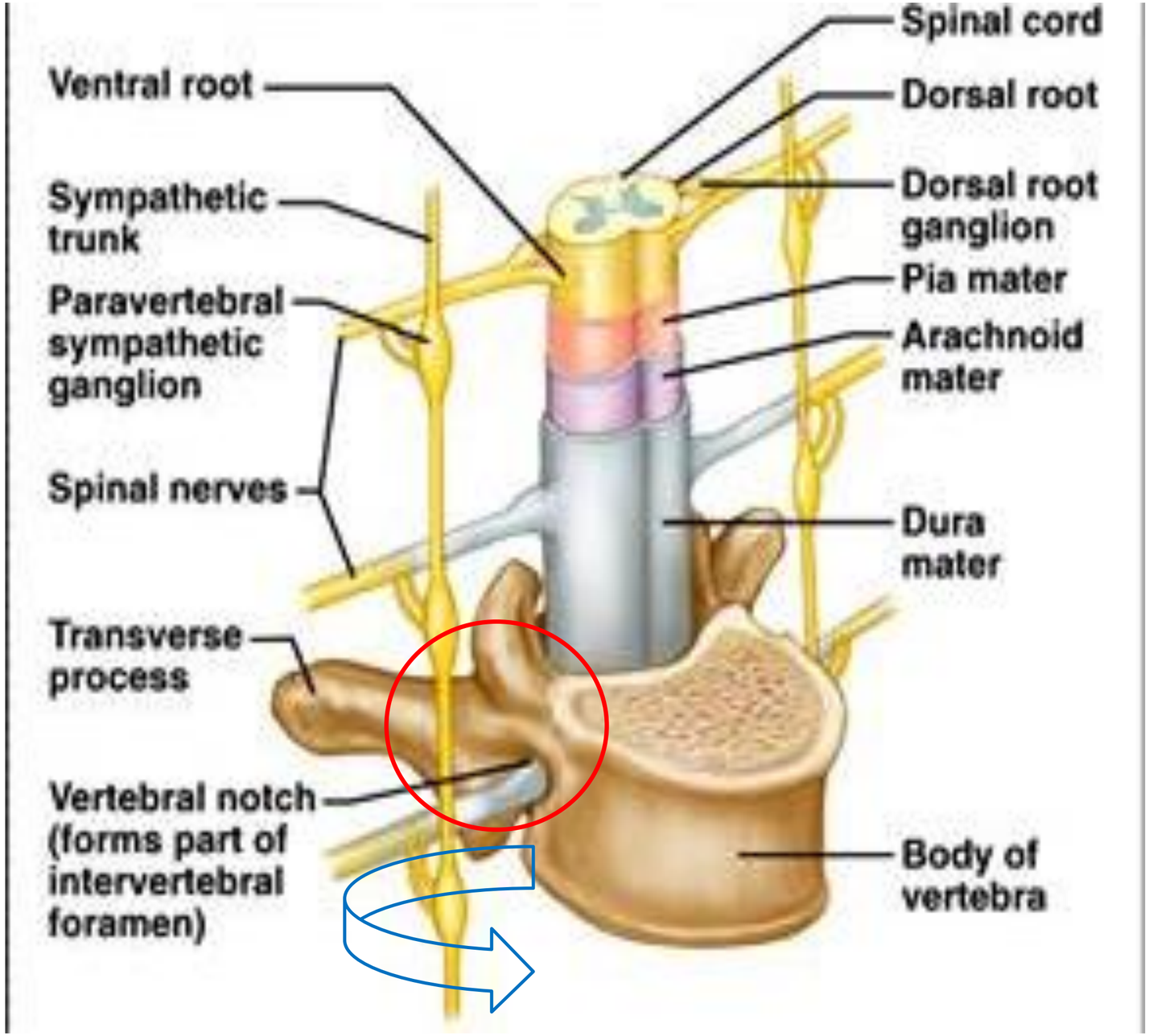
Spinal cord
Ventral root
Dorsal root
Sympathetic trunk
Dorsal root ganglion
Pia mater
Paravertebral sympathetic ganglion
Arachnoid mater
Spinal nerves
Dura mater
Transverse process
Vertebral notch (forms part of intervertebral foramen)
Body of vertebra

Innervation of Heart

Schema

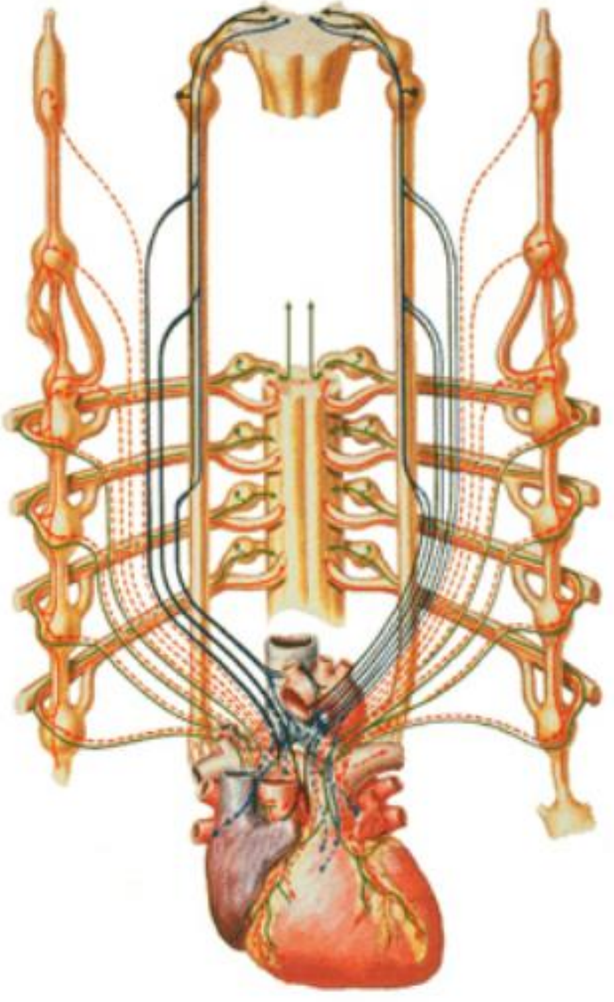

Neck vulnerable injury area: cervico-dorsal

- ✓ C5, C7-T1 (Neck vulnerable injury area: cervico-dorsal)
- ✓ C5: Cervical curvature.
- ✓ More muscles insertions.
- ✓ Area of muscle tension concentration.
- ✓ Area of the Sympathetic ganglion trunk.
- ✓ Area of Parasympathetic ganglion trunk.
- ✓ Area of the brachial plexor.

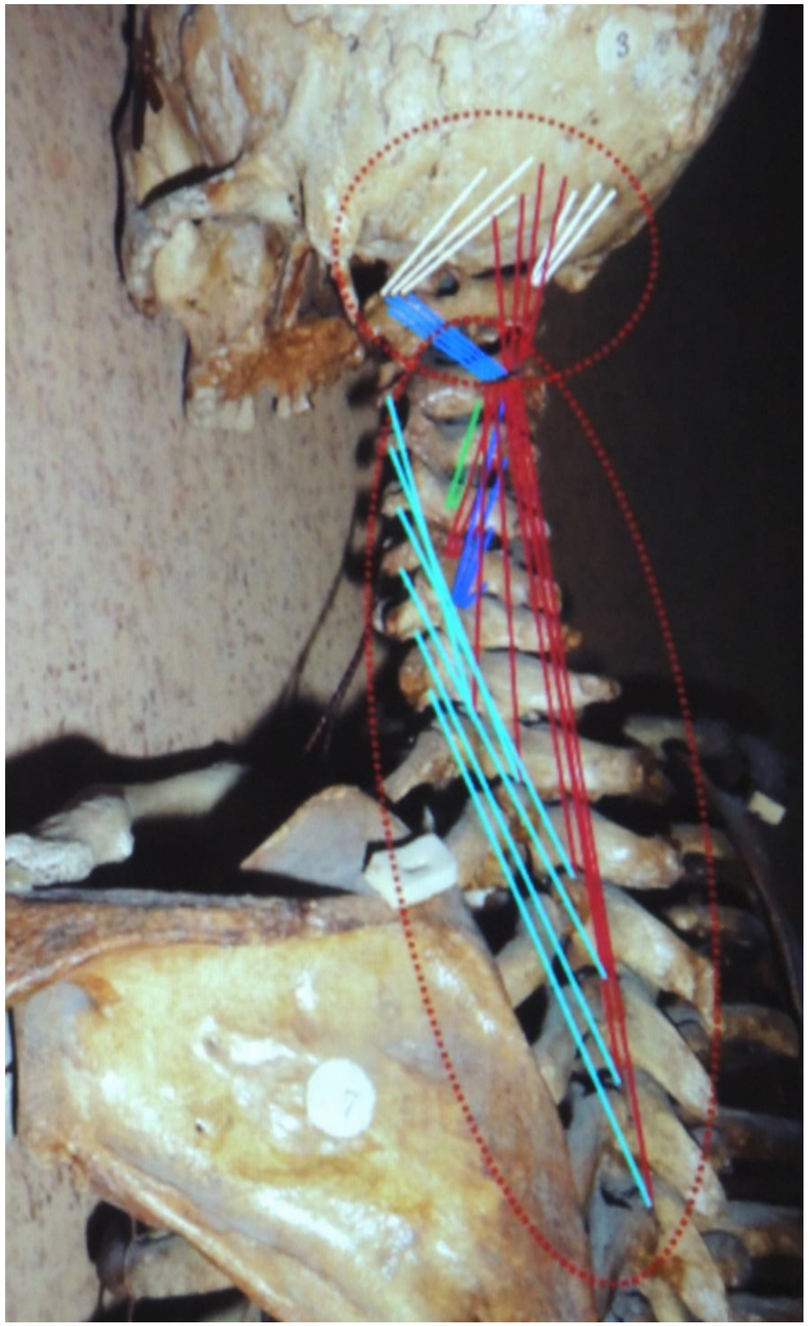

颈胸结合部是易损区

颈胸结合部是指C5、C6、C7和T1、T2、T3，尤其是C6、C7和T1、T2。
该处有以下特征：
1.动静结合部
2众多肌肉附着处，
3.力的交汇点
4.交感N系统的重要通道
5.副交感N系统的重要通道
6.臂丛N的重要通道

Anterior cervical muscles 颈前肌
(Scalene muscles)

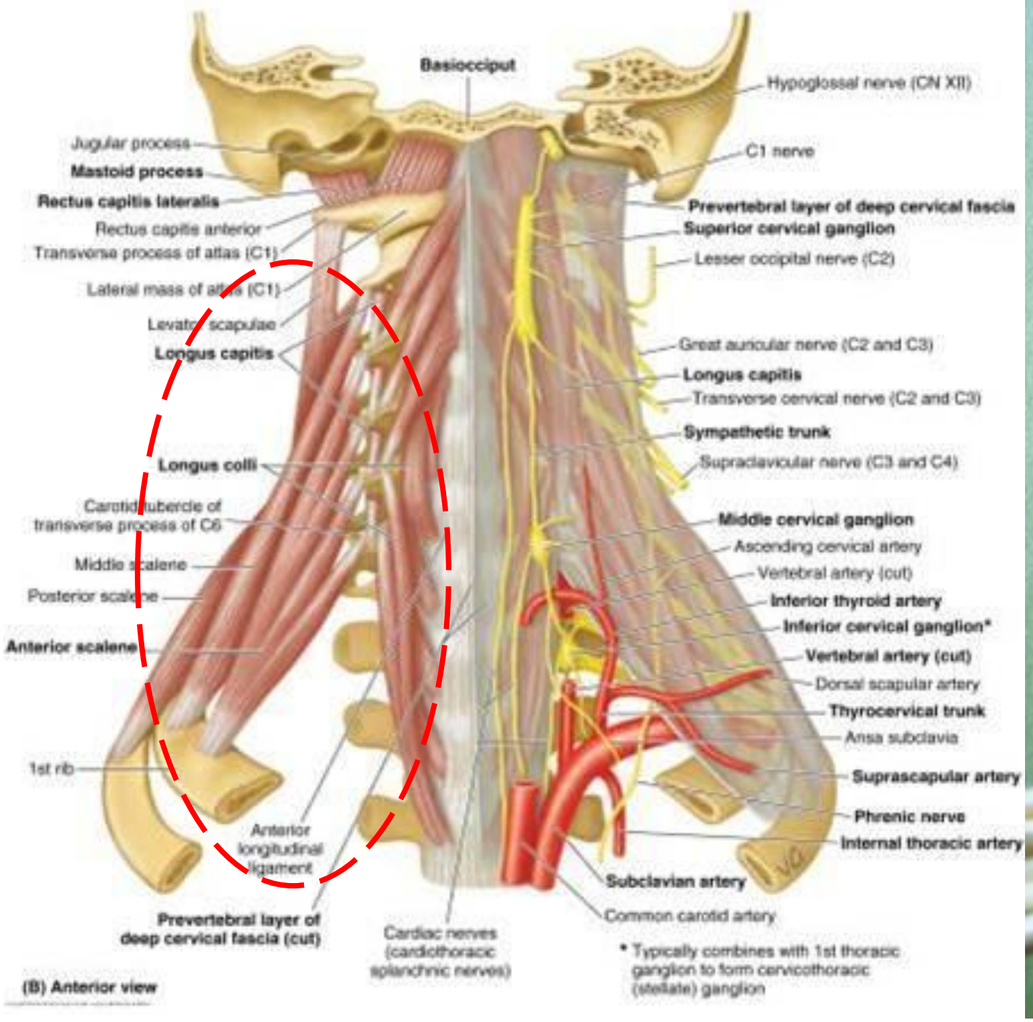

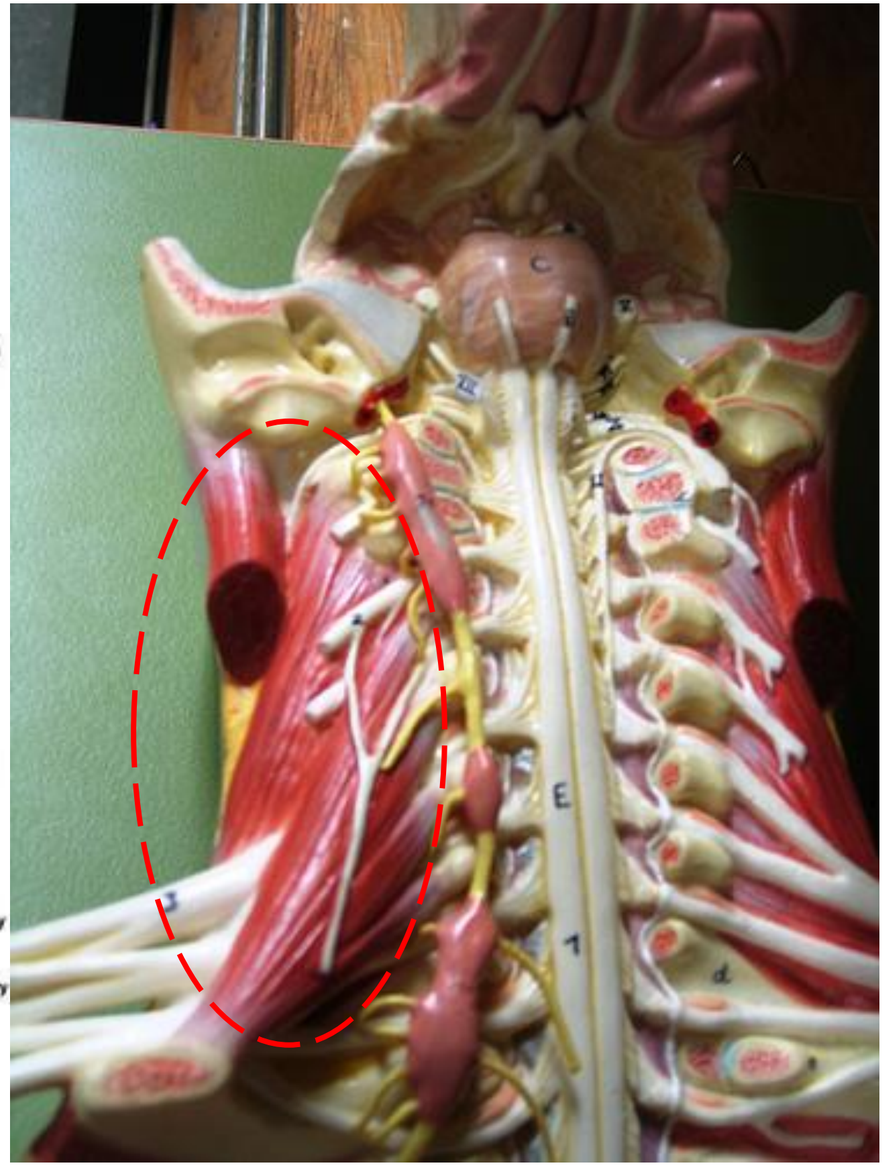

Location of Sympathetic ganglions:
The lower edge of the rib tubercle
close to the Foot Taiyang UB meridian 1st. medial line
(with each visceral Shu points)

交感神经节位置: 肋骨节结下缘
近足太阳膀胱经第一内侧线(各内脏俞穴位置)

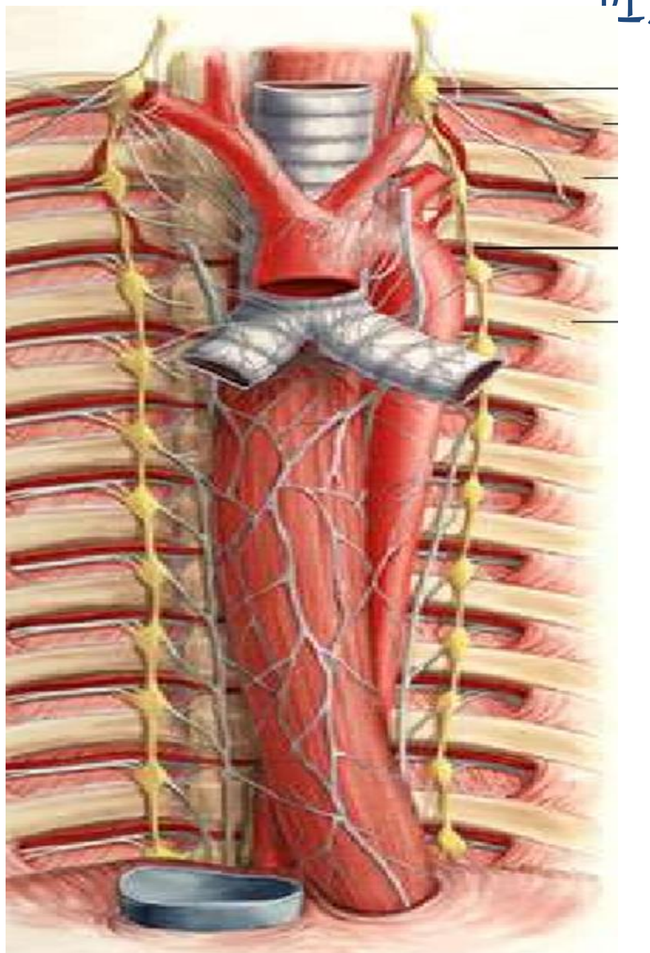

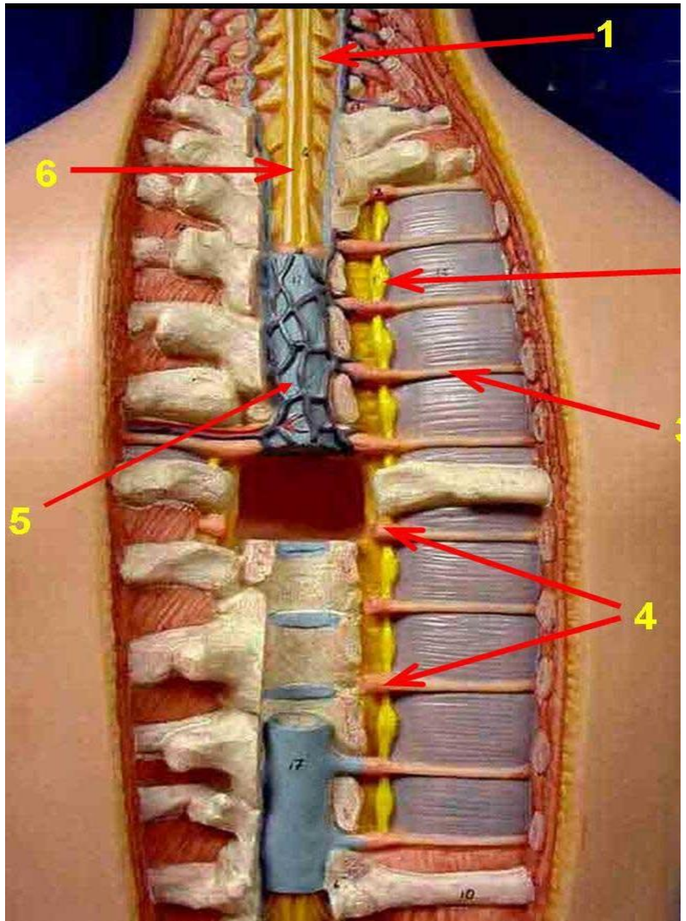

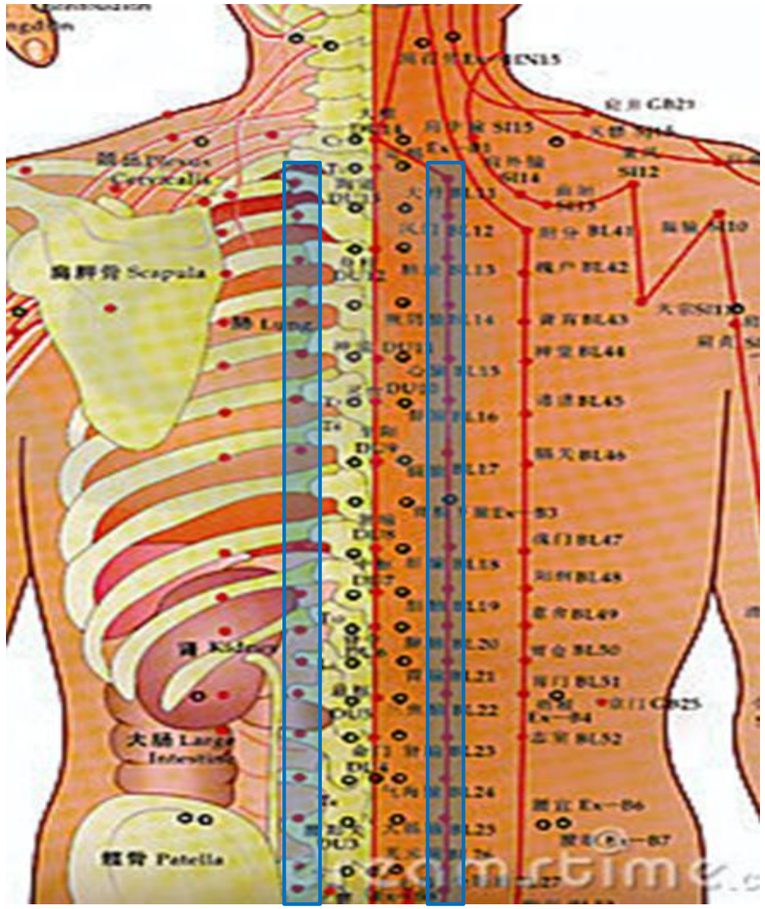


TAKE A
BREAK
COFFEE TIME!

Thyroid Disorder Treatment with Acupuncture

1. Occipital area

Lorem ipsum dolor sit amet, consectetur adipiscing elit. Curabitur tincidunt dictum congue. Quisque nunc magna, vulputate eget bibendum ut, posuere sit amet magna. Nunc hendrerit, urna at ultrices lacinia, dolor nunc posuere eros, a ultricies diam tellus vitae felis. Cras viverra vel velit id tristique. Maecenas porttitor vitae leo quis iaculis.

2. Cervical – Thoracic area

Lorem ipsum dolor sit amet, consectetur adipiscing elit. Curabitur tincidunt dictum congue. Quisque nunc magna, vulputate eget bibendum ut, posuere sit amet magna. Nunc hendrerit, urna at ultrices lacinia, dolor nunc posuere eros, a ultricies diam tellus vitae felis. Cras viverra vel velit id tristique. Maecenas porttitor vitae leo quis iaculis.

3. Neck frontal area

Lorem ipsum dolor sit amet, consectetur adipiscing elit. Curabitur tincidunt dictum congue. Quisque nunc magna, vulputate eget bibendum ut, posuere sit amet magna. Nunc hendrerit, urna at ultrices lacinia, dolor nunc posuere eros, a ultricies diam tellus vitae felis. Cras viverra vel velit id tristique. Maecenas porttitor vitae leo quis iaculis.

Posterior neck muscles
颈后肌

Contracted muscles that could cause “displacement” of the C5 – T1 vertebrae:

- ✓ Trapezius
- ✓ Splenius capitis
- ✓ Levator scapulae
- ✓ Rhomboid minor
- ✓ Suboccipital muscles

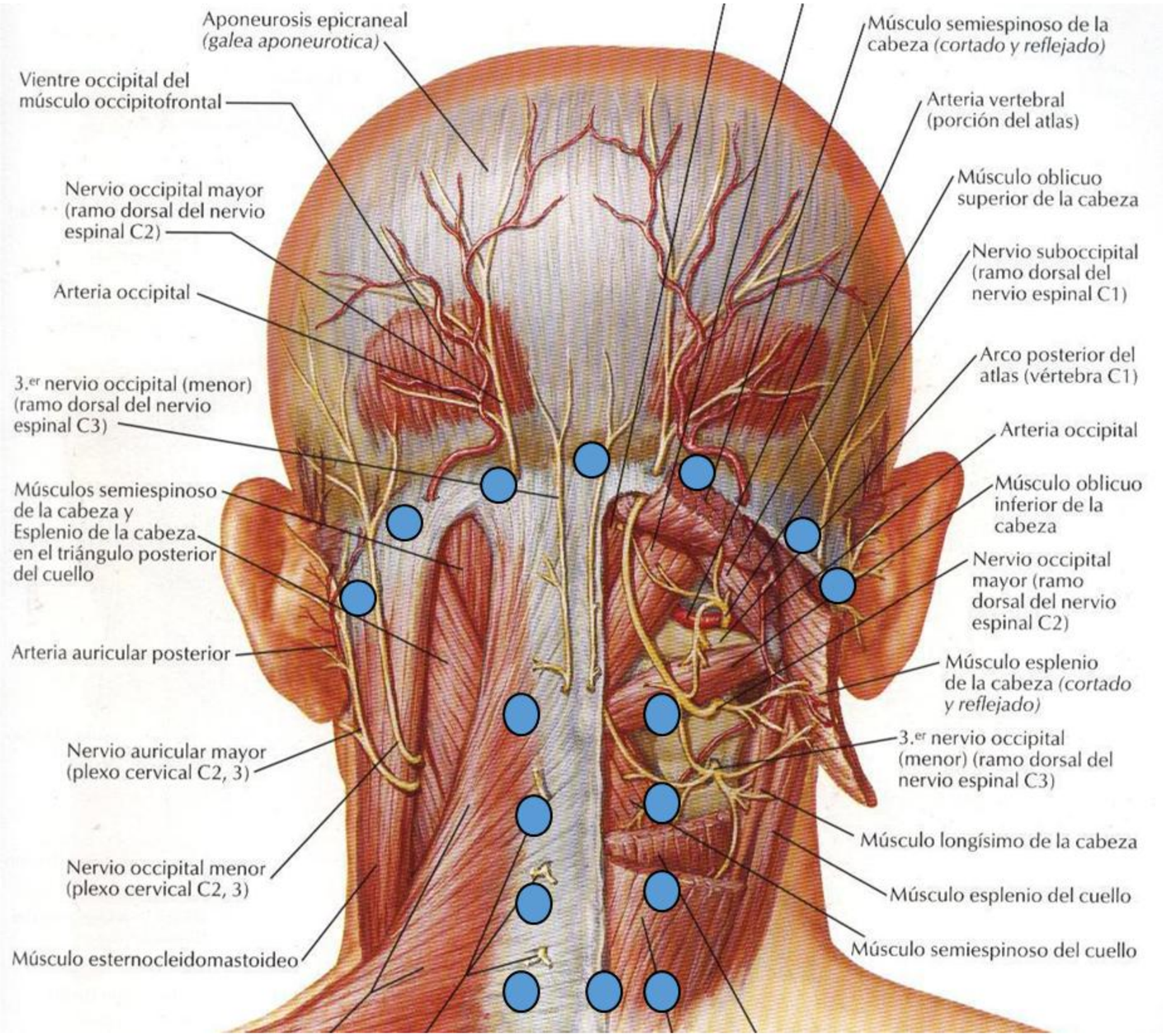

Cervical muscle vulnerable be injured
颈部易损伤肌群

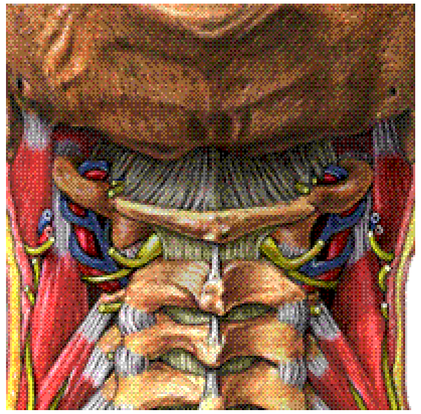
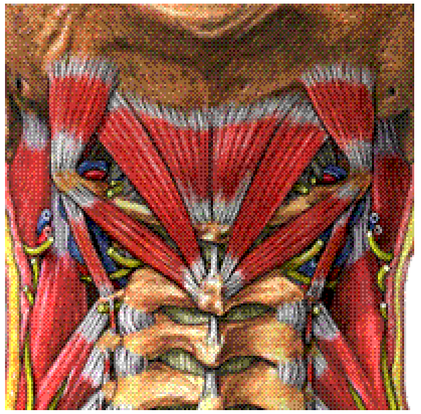
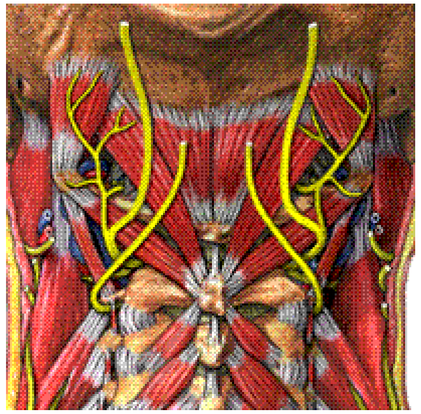
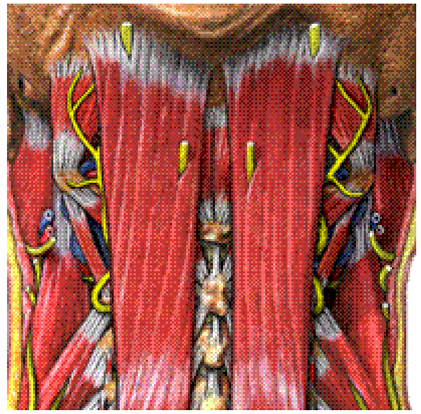
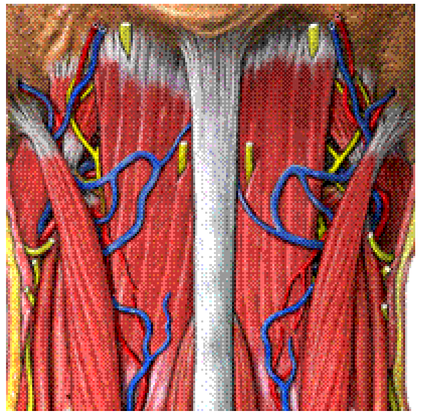
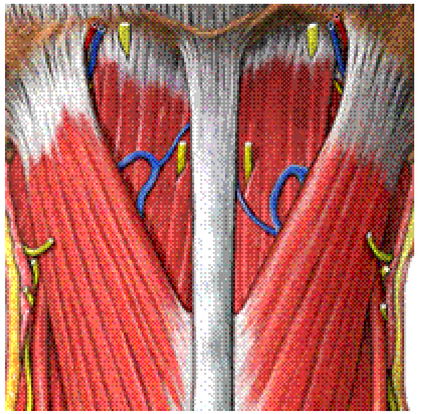
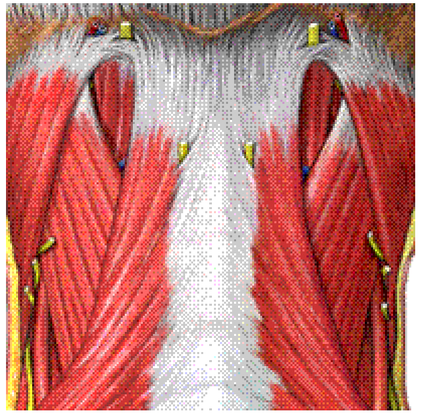
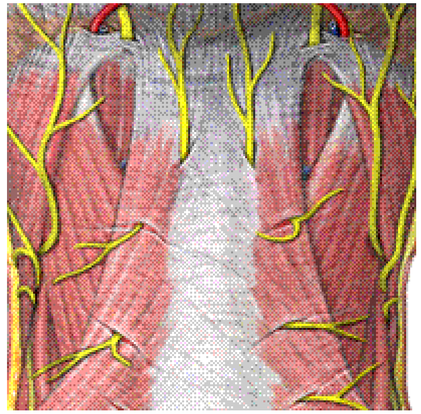

Etiology & Pathology 病因病理

- ✓ Atlantoaxial displacemente寰枢椎半脱位
- ✓ Inferior cervical vertebrae disorders下部颈椎椎节不稳
- ✓ Vertebral spiral displacement 椎体螺旋性移位

Irritation/traction/compression

直接刺激/牵拉/压迫

Sympathetic nerve fibers

交感神经纤维

Etiology & Pathology 病因病理

- ✓ Vertebral disc herniation椎间盘突出
- ✓ Uncovertebral joint degeneration钩椎关节增生

- ✓ Cervical epidural 颈段硬脊膜
- ✓ The posterior longitudinal ligament后纵韧带
- ✓ Small joints小关节
- ✓ Cervical nerves roots 颈神经根
- ✓ Cervical vertebral artery 椎动脉

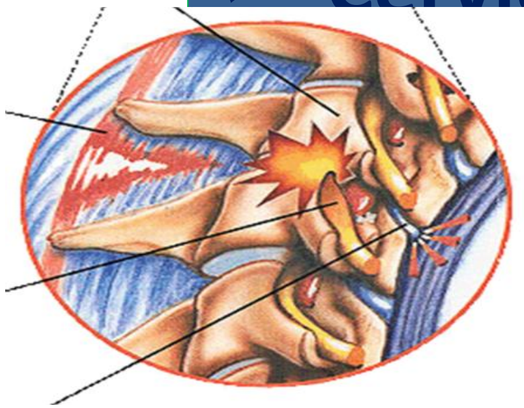

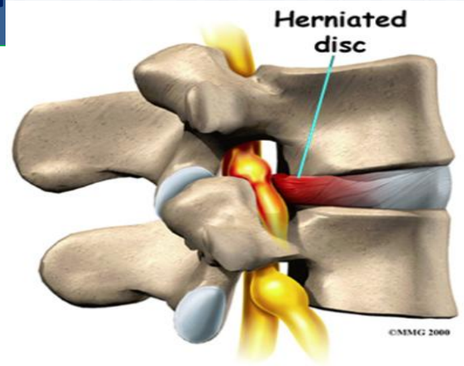

Reflex irritation反射性刺激

Sympathetic nerve fibers
交感神经纤维

Sports injury 运动伤害

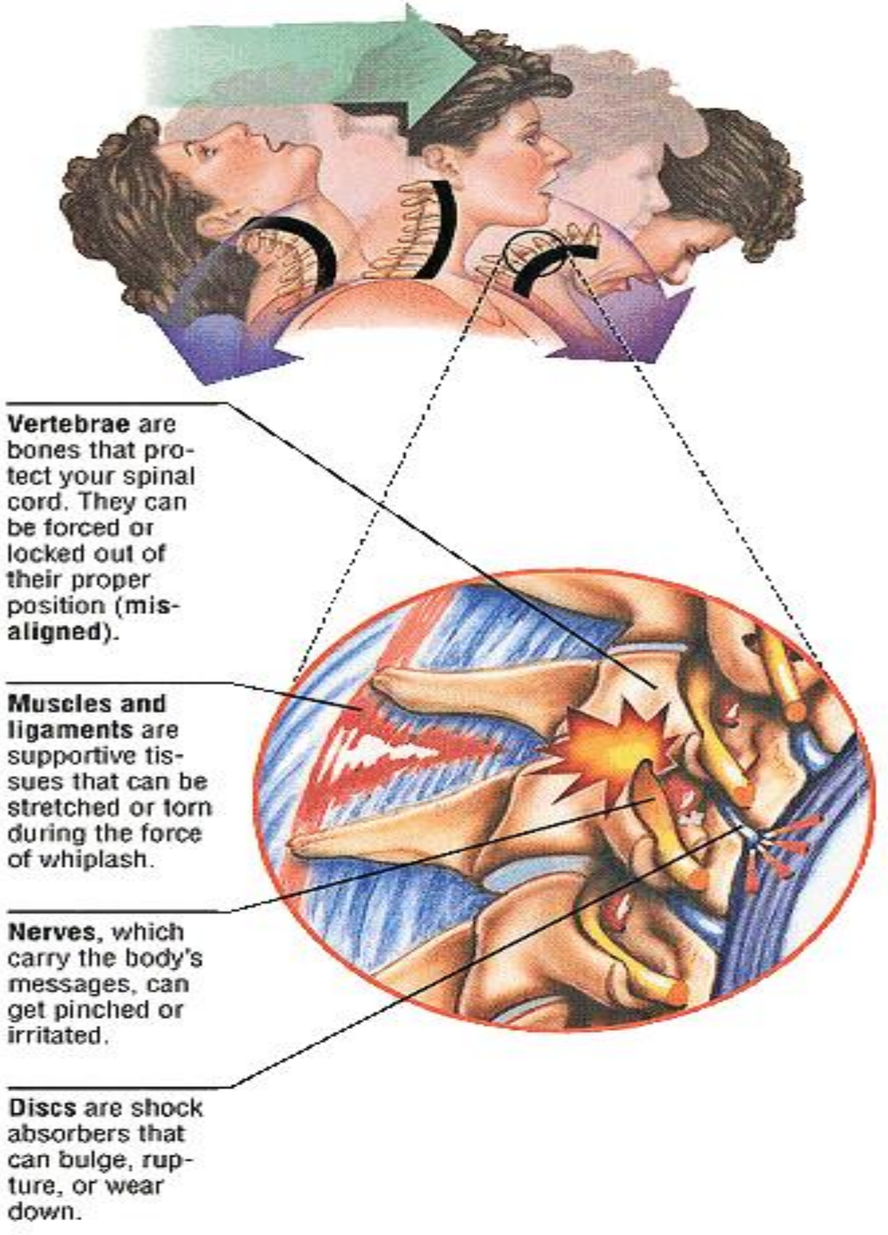
Vertebrae are bones that protect your spinal cord. They can be forced or locked out of their proper position (**misaligned**).
Muscles and ligaments are supportive tissues that can be stretched or torn during the force of whiplash.
Nerves, which carry the body's messages, can get pinched or irritated.
Discs are shock absorbers that can bulge, rupture, or wear down.


Whiplash

Job injury
工作劳损

Job injury
工作劳损

Bad postures
不良姿势

Bad postures
不良姿势



Bad postures
不良姿势



Bad postures
不良姿势

Bad postures
不良姿势

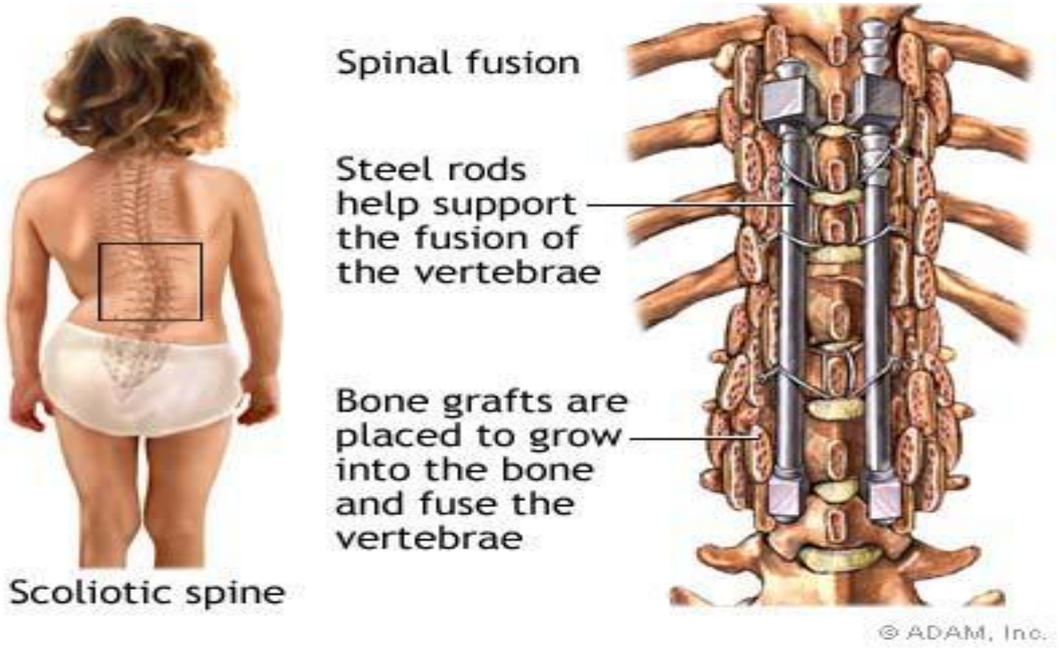
Spinal fusion
Steel rods help support the fusion of the vertebrae
Bone grafts are placed to grow into the bone and fuse the vertebrae
Scoliotic spine
© ADAM, Inc.

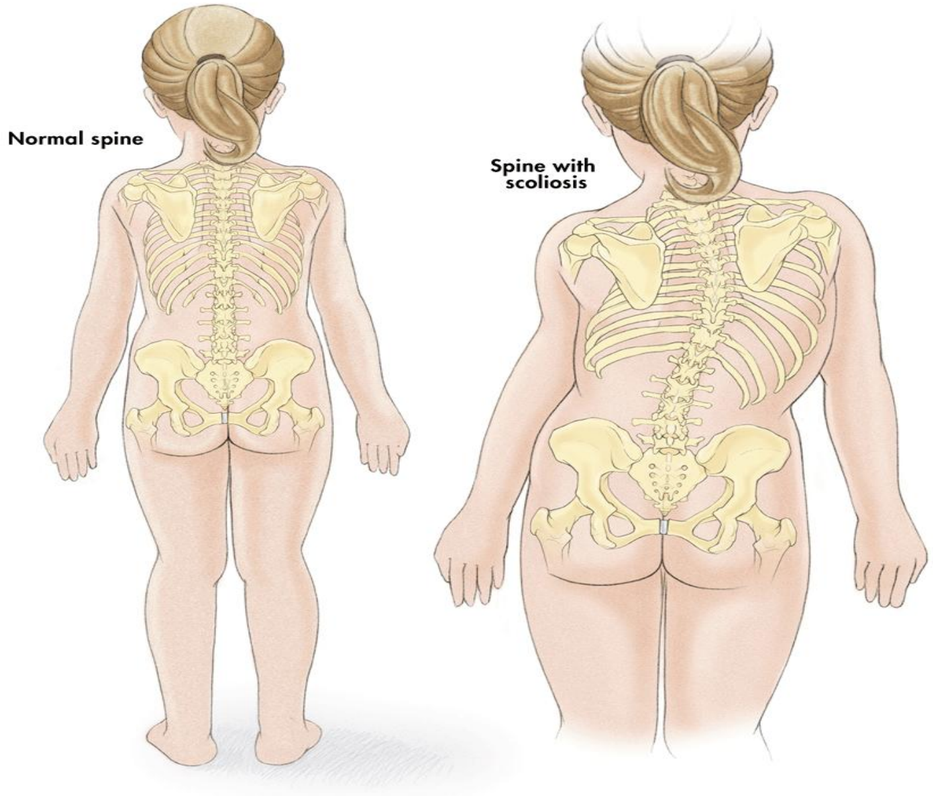
Normal spine
Spine with scoliosis


Before

Dropped Head Syndrome

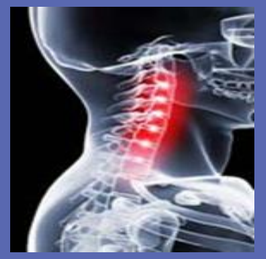

Suboccipital contents

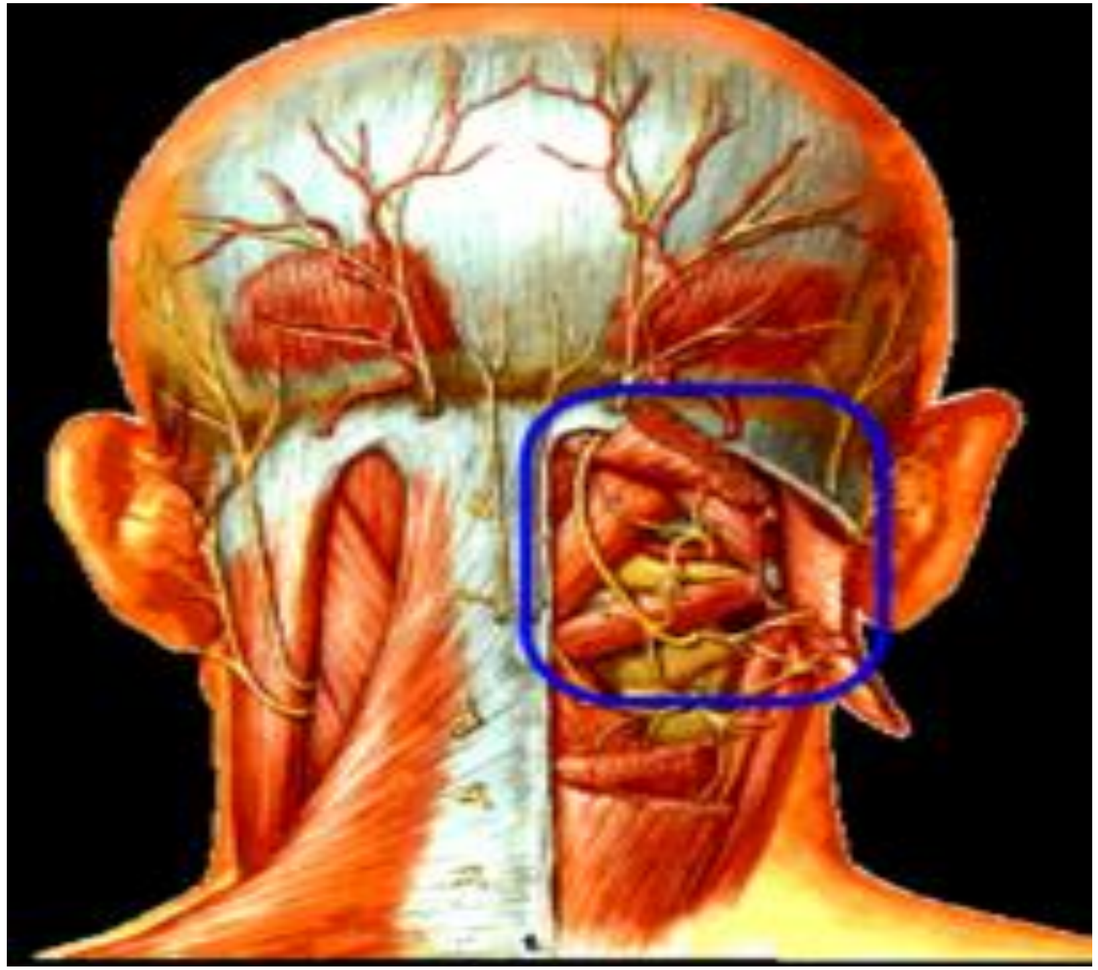

- **Suboccipital triangle:**
  - Obliquus capitis superior
  - Obliquus capitis inferior
  - Rectus capitis major
- **Greater occipital nerve**
- **Suboccipital nerve**
- **Vertebral artery**

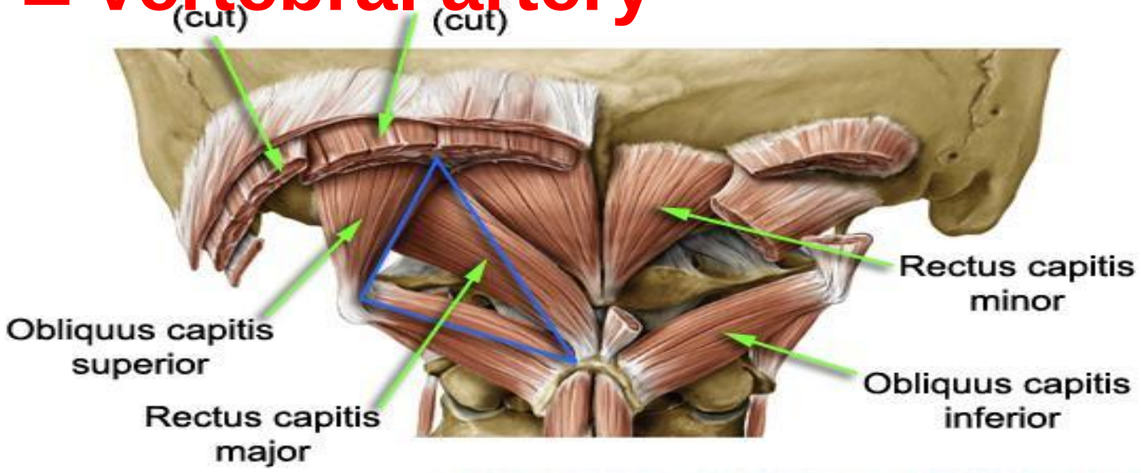

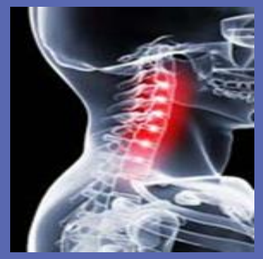

6 curvatures of segment 3

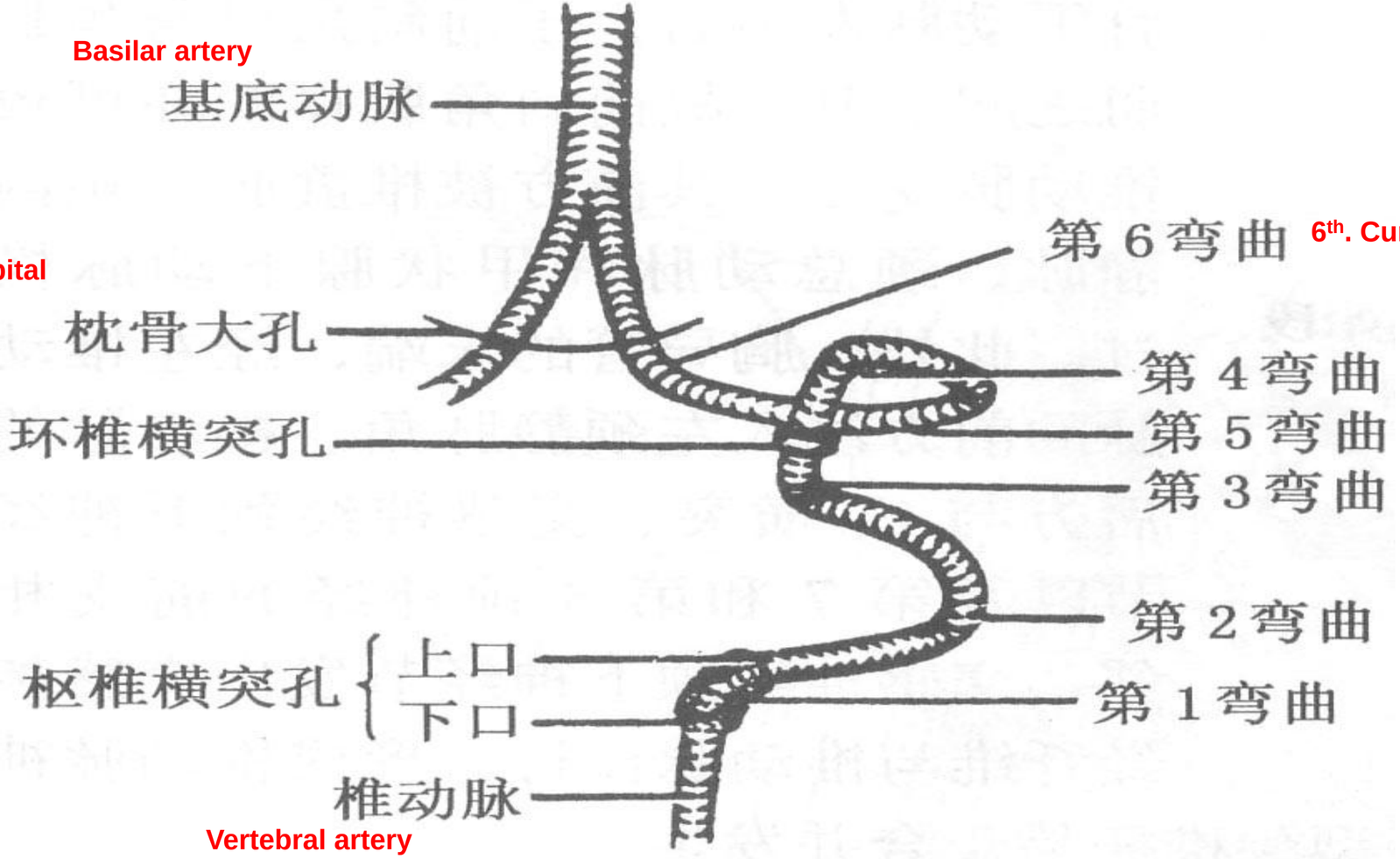

图 2－82　椎动脉第 3 段的 6 个弯曲模式

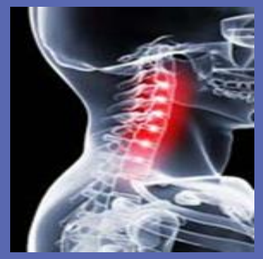

Transverse Process section Segment 2

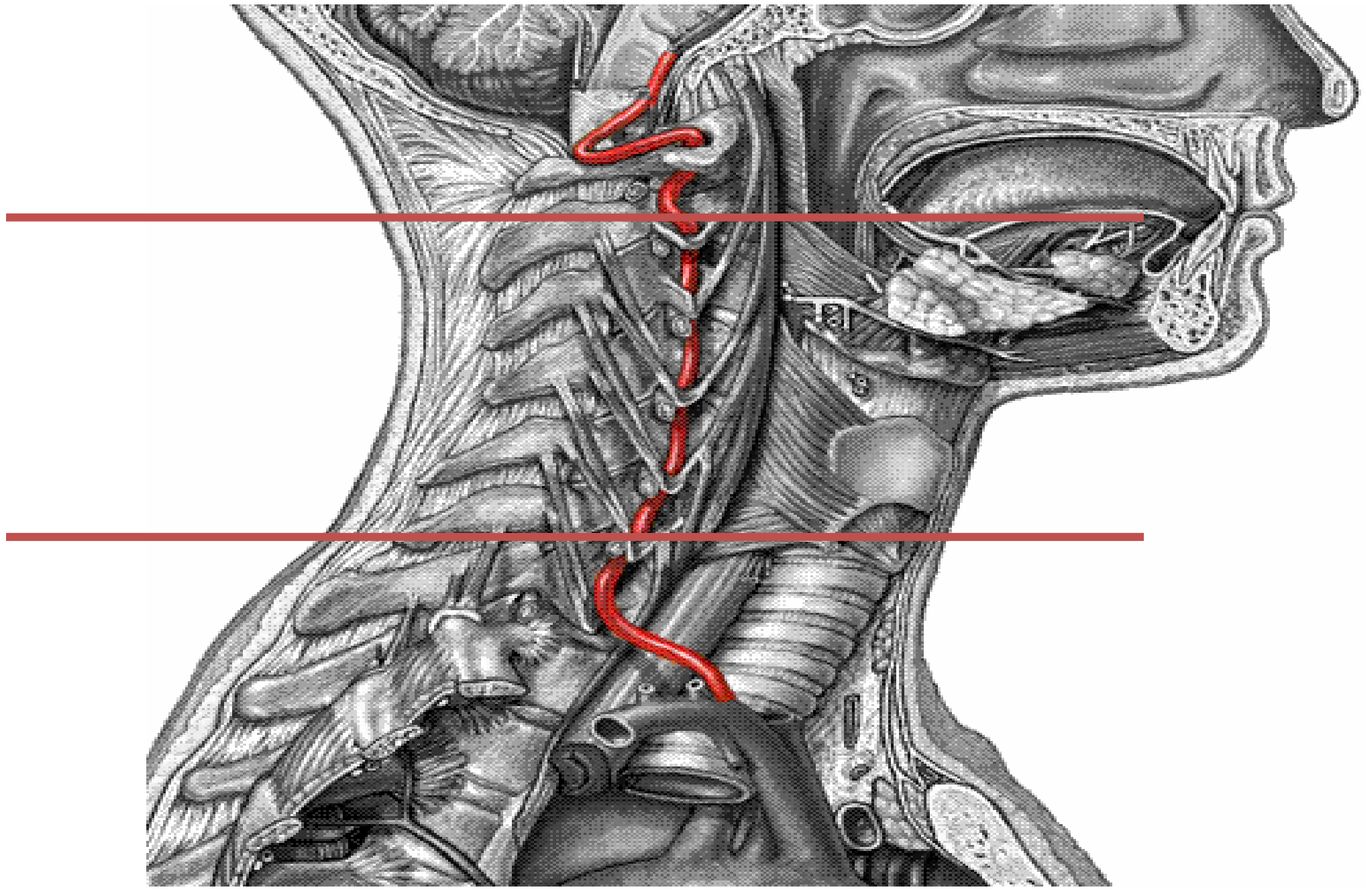

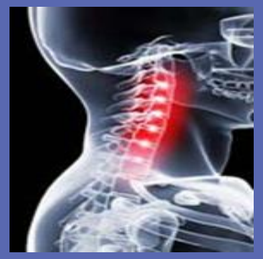

Curvature changes

- Loosing curvature
- Became to straight
- Against curvature (Kyphosis)

弧度改变

Became to straight

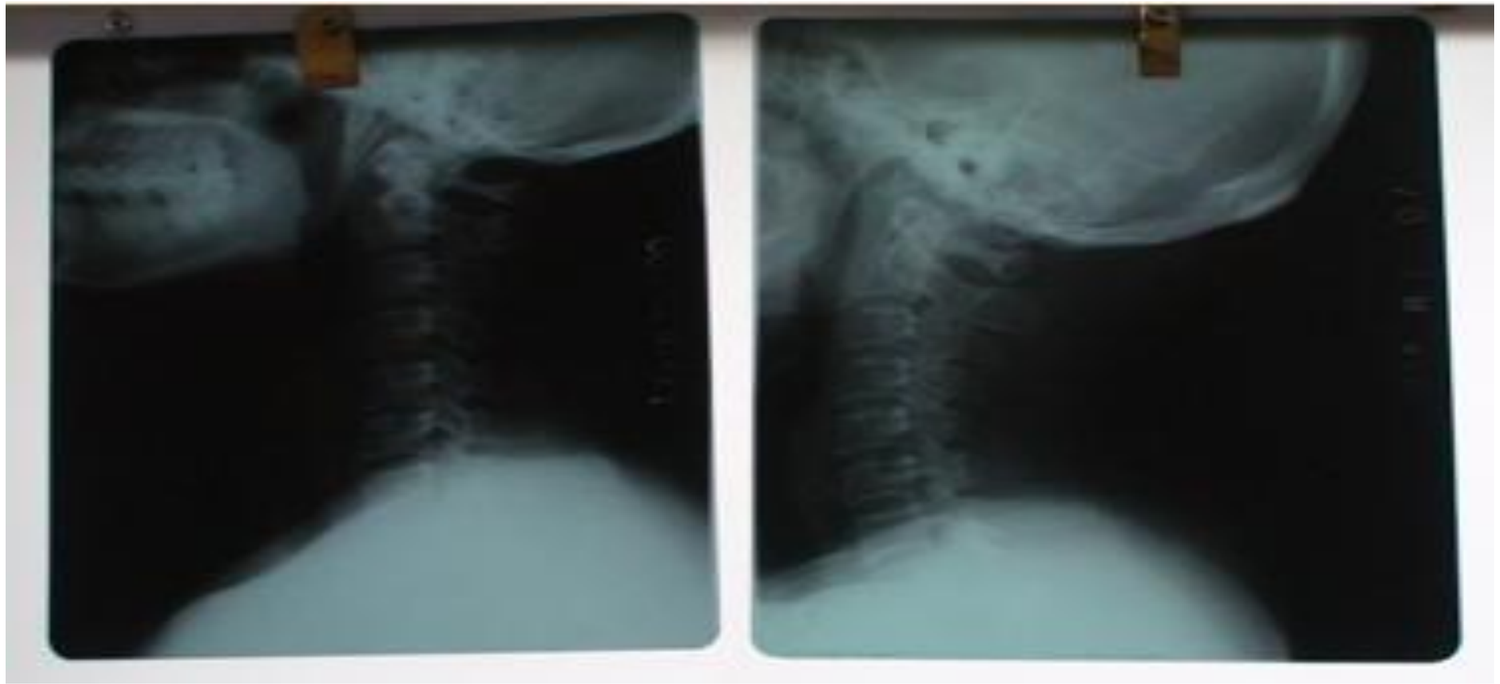

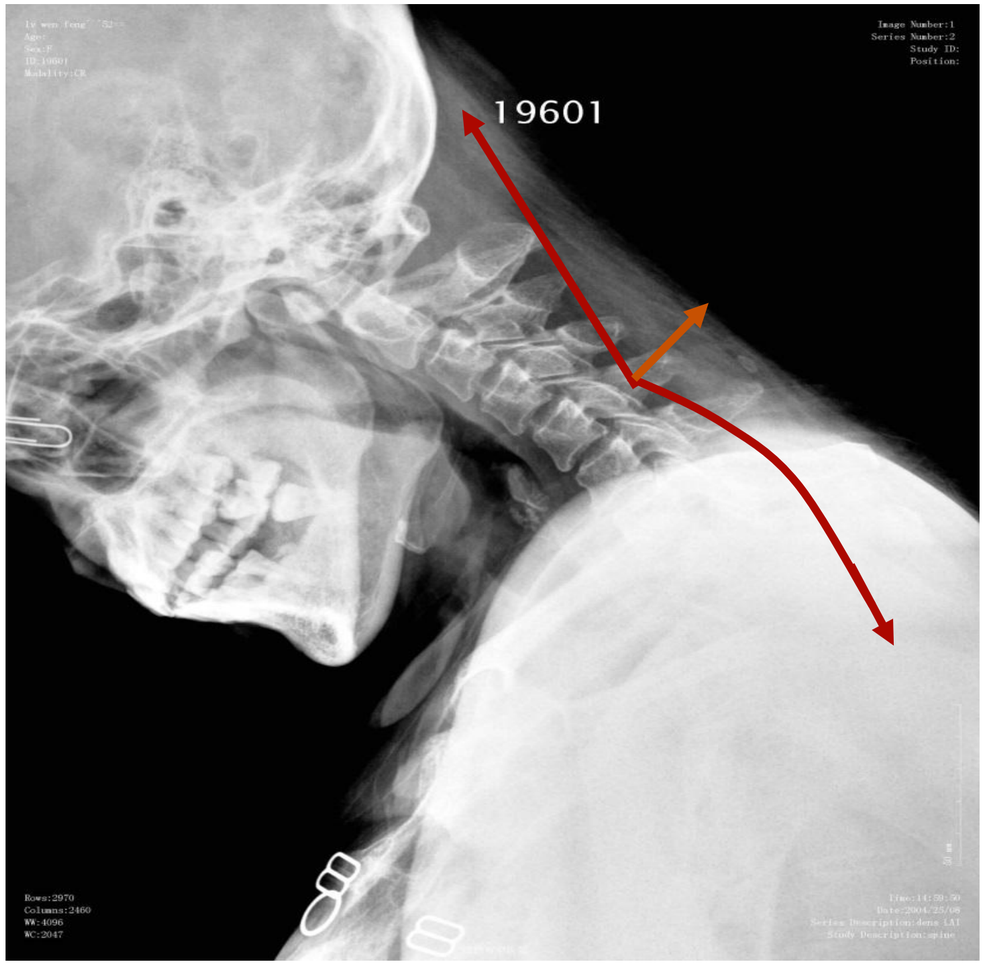

- **C4-C5** is the **top** of cervical curvature, the most vulnerable region.
- **C4-C6** are the **most vulnerable** vertebrae in the Section II.

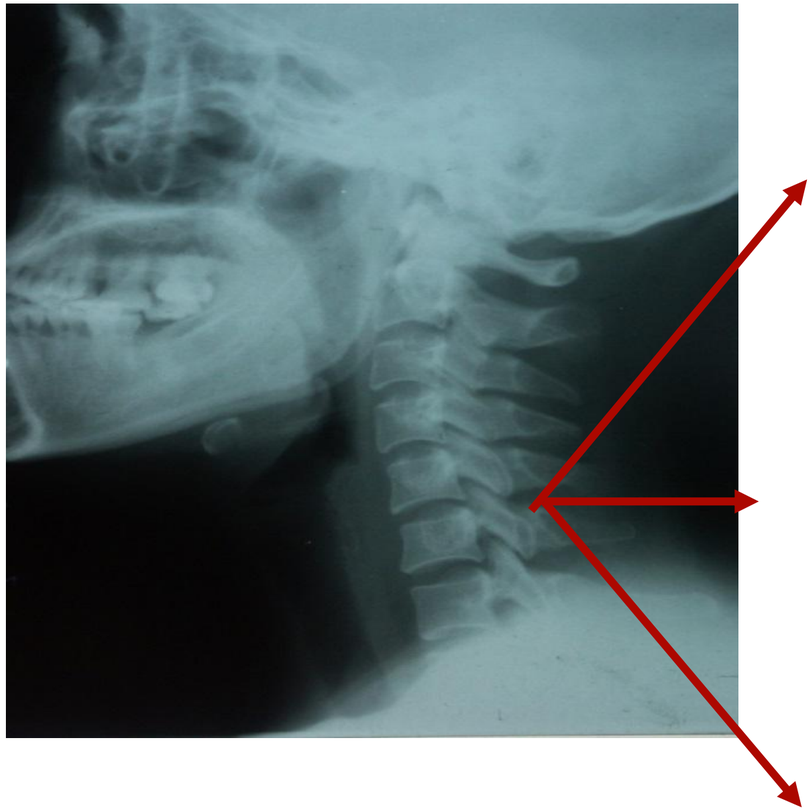

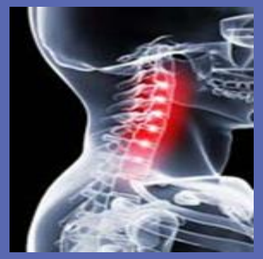

Important soft tissue Related to the CS

- **Fascia:**
- Nucha & back superficial & deep fascia
- **Ligaments:**
- Supraspinal ligament
- Interspinal ligament
- Posterior longitudinal ligament
- Flavum ligament
- Intertransversal ligament
- **Articular capsules:**
- Superior & inferior articular process capsules
- **Muscles:**
- Trapezius, Levator scapulae, Sternocleidomastoid, Splenius capitis, Scalene, Rectus capitis major & minor, Obliquus capitis superior & inferior, Rhomboids major & minor, etc.
- **Nerves:**
- Spinal cord, spinal nerves, sympathetic trunk, ganglion of autonomic nerves, plexus, etc.

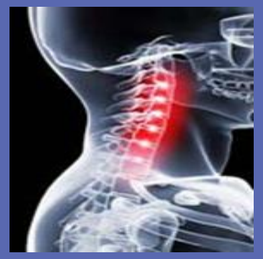

Neck & Nuchal muscles

Neck muscles:

Anterior parte of **Trapezius** anterior edge.

- **Neck muscles:**
- **Sternocleidomastoid**
- Neck deep muscles: **Scalene anterior, medium, posterior**.
- The **brachial plexus** pass through the **Scalene** muscles, this group muscle spasms, may compress the brachial plexus, leads to the **Scalene muscles syndrome**.

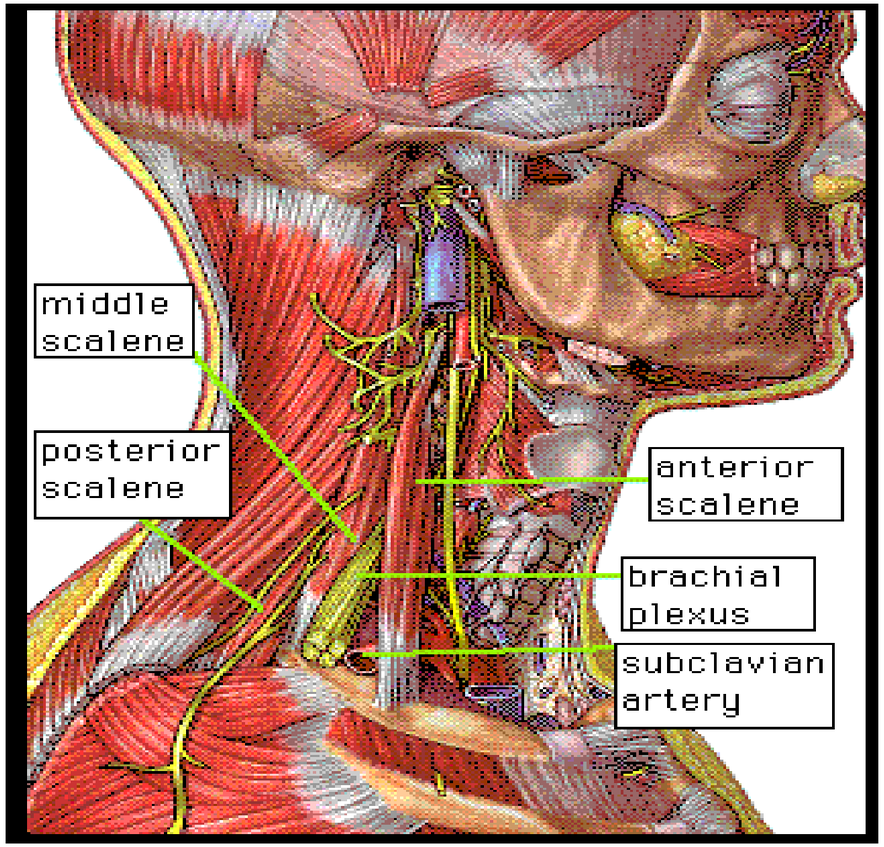

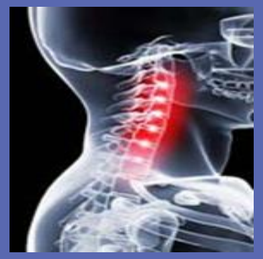

Neck & Nuchal muscles

Nuchal muscles:

Posterior parte of Trapezius anterior edge.

Nuchal muscles:

- Trapezius
- Levator Scapulae
- Rhomboid
- Serratus superoposterior
- Splenius capitis
- Erector spinae:
  - Iliocostalis cervicis
  - Longissimus cervicis
  - Spinalis cervicis
- Semispinalis capitis/cervicis
- Multifidus cervicis
- Rotatores cervicis
- Intertransverse
- Interspinal
- Suboccipital muscles:
  - Rectus capitis major & minor
  - Obliquus capitis superior & inferior


Break
Time

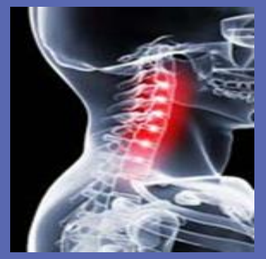

Cervical Vertebrae Safety area

- **Uncovertebrae joint area**
- **关节突关节**

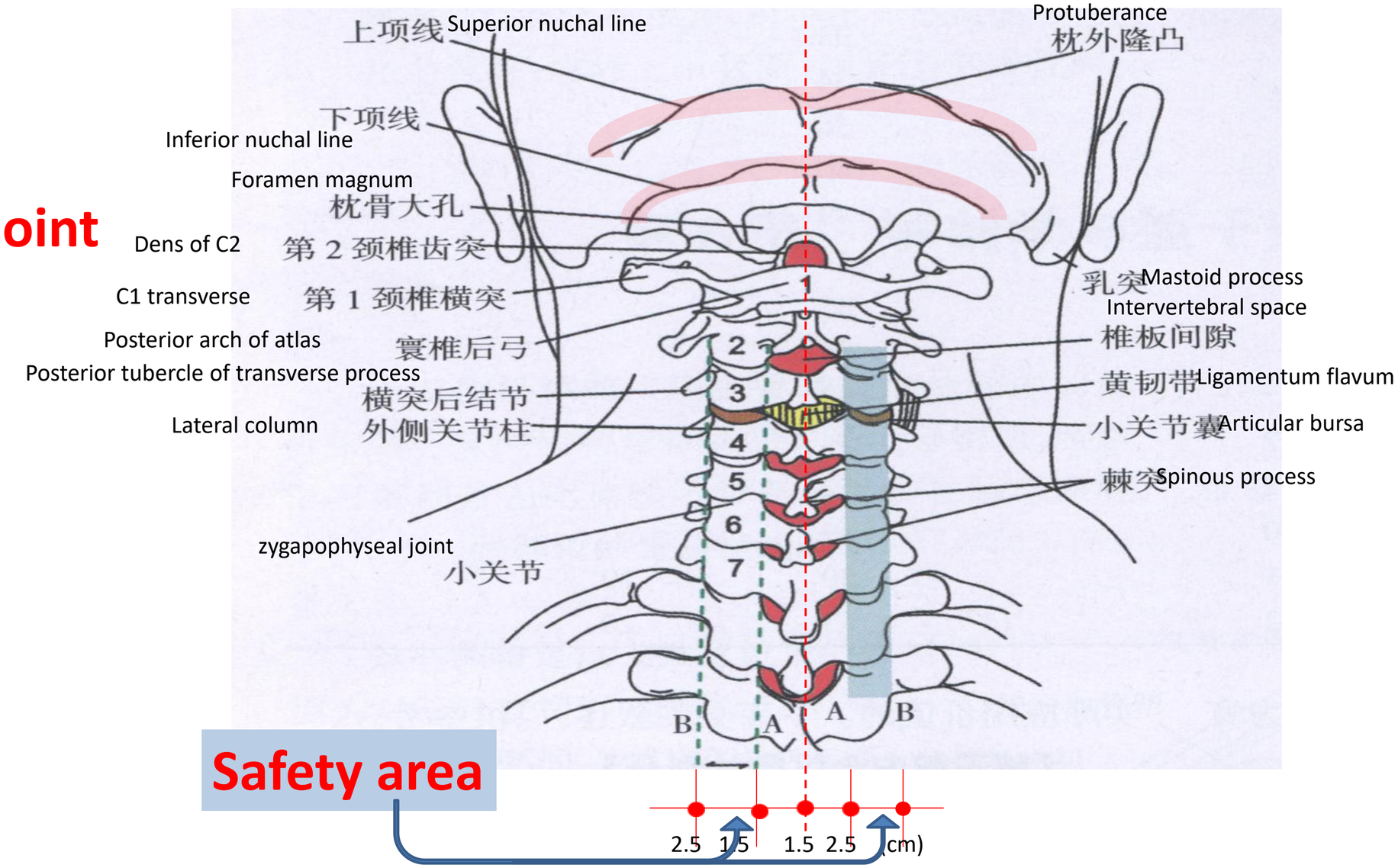

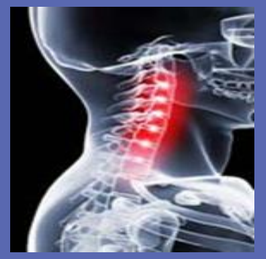

Cervical Vertebrae Safety area

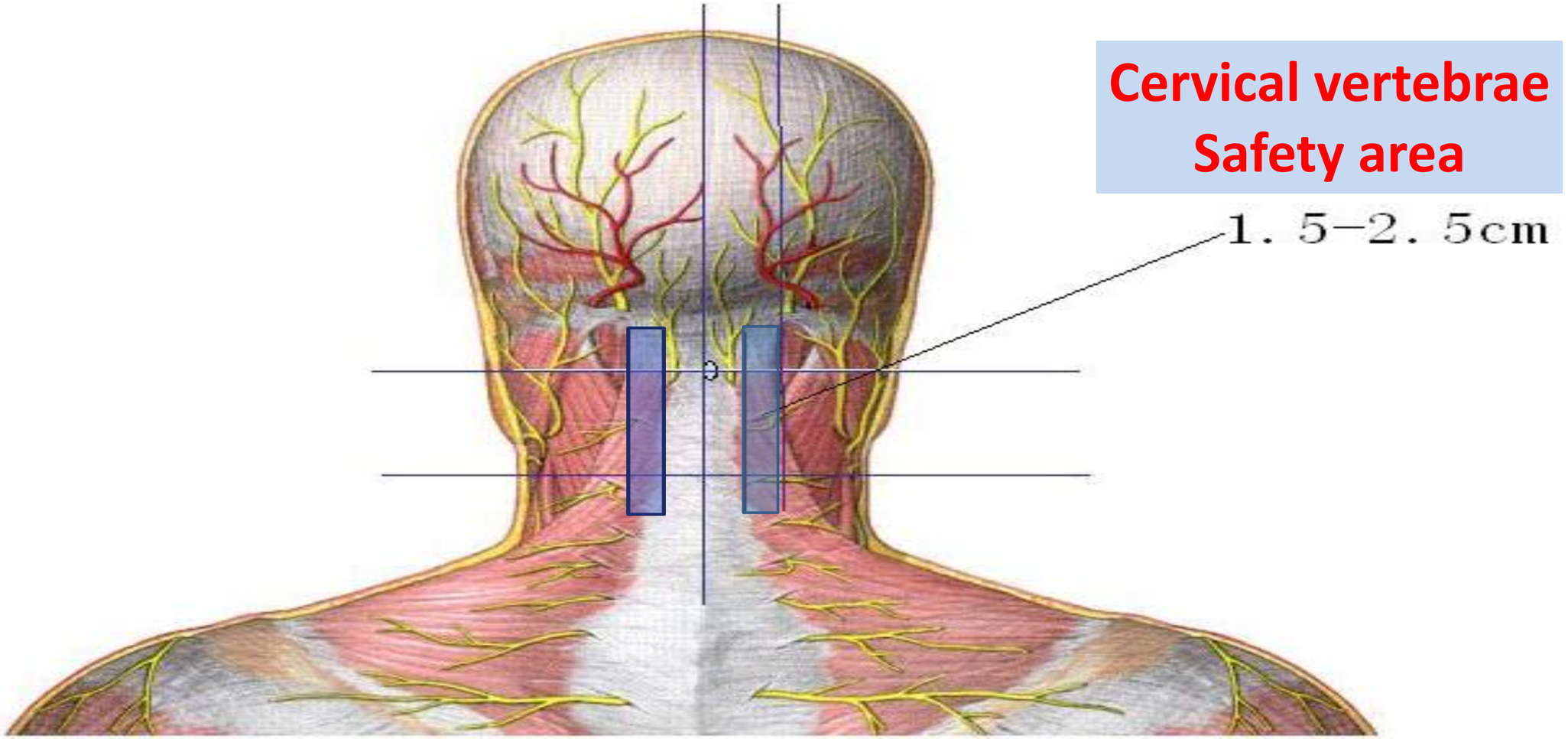

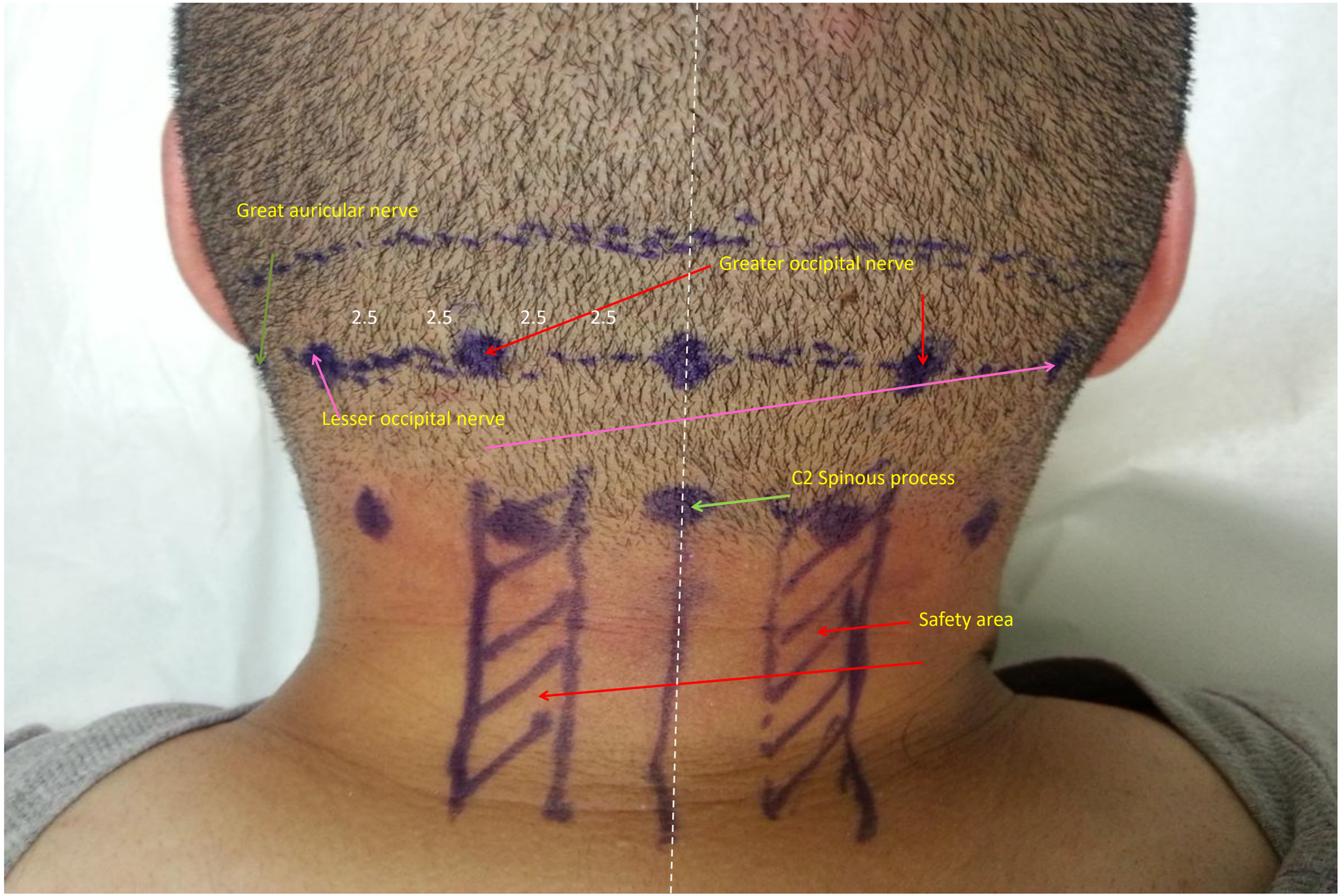
Great auricular nerve
Greater occipital nerve
2.5
2.5
2.5
2.5
Lesser occipital nerve
C2 Spinous process
Safety area

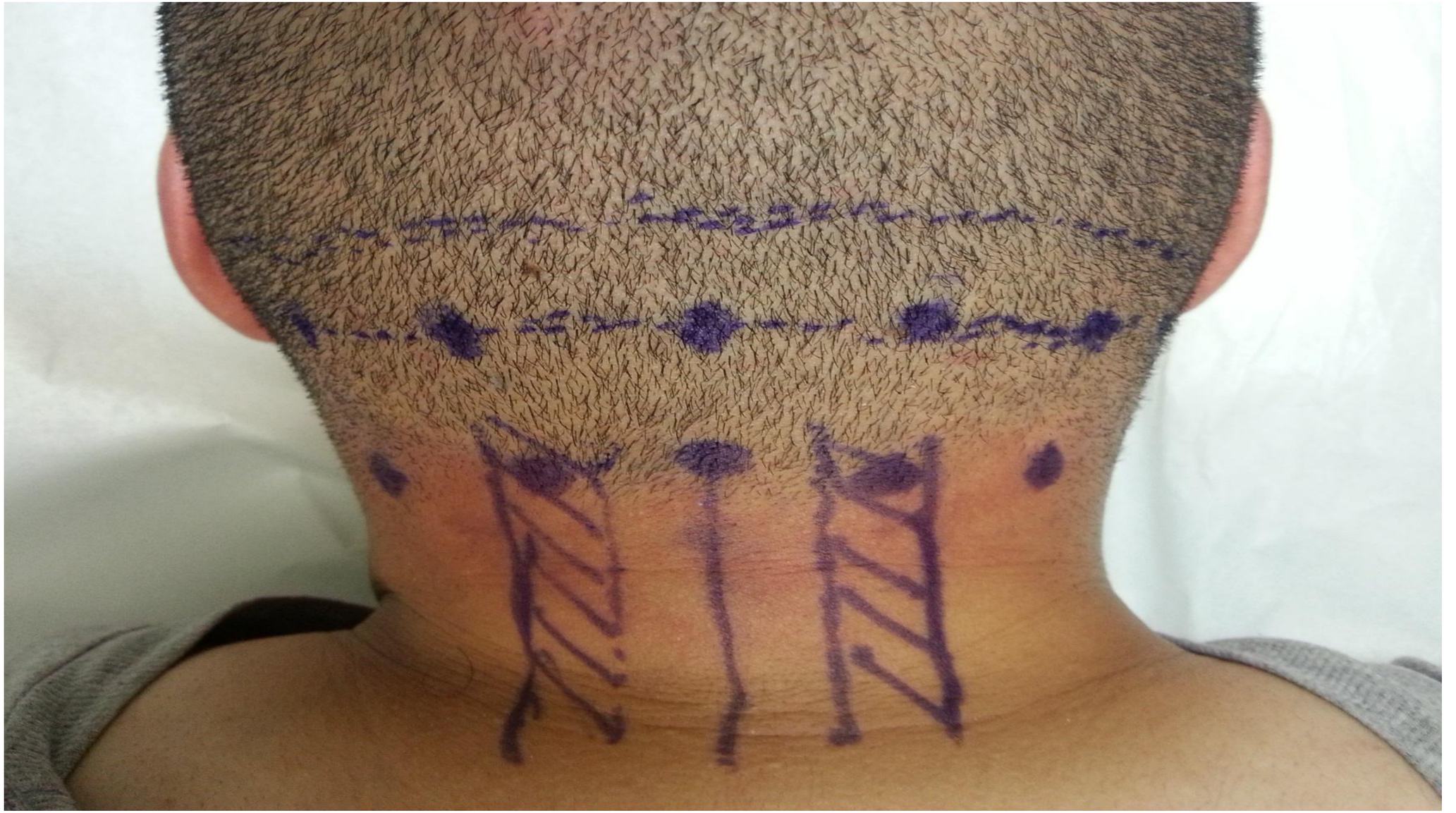

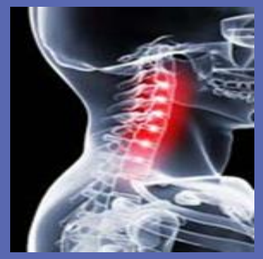

Remark area 重点

1. The most vulnerable area of CS:

a. Atlantooccipital space (Aponeurosis)

b. Atlantoaxial joint

c. Suboccipital triangle

d. C5, C6 interspinous ligament, posterior articular process

2. Displacement or luxation of articular joints, should apply the adjustment technique.

3. Cervical soft tissue injury (3 points with 5 points):

Tianzhu (UB10), Tianliao (SJ15) bilateral.

Dazhui (Du14) unilateral.

4. Precaution areas:

a. Aponeurosis Atlantooccipital

b. Ligamentum flavum

c. Transversal process

d. Intervertebral foramen

1. 椎动脉型颈椎病容易出问题的部位是：
   寰枕间隙(寰枕筋膜）
   寰枢关节
   枕下三角
   C5、C6棘间韧带、后关节突
2. 小关节错位或半脱位，手法整复是治疗关键。
3. 软组织损伤型，可采用“三穴五点”：
   三穴: 天柱、大椎、天髎。
   天柱、天髎均为双侧。加大椎，共为五点。
   另加：肩胛骨内上角
4. 危险部位：寰枕后膜、黄韧带、横突尖、椎间孔。

Treatment 治疗

1.1. Atlanto-occipital 寰枕关节

1. Patient prone.
2. Landmarks:

✓ Protuberance, C2 spinous process, posterior hairline, trapezius.

3. Points locations: (3 points)

✓ Nuchal area, 3.5cm upper of the midpoint hairline. (or 2~3cm lower of the inferior border of occipital protuberance), the depression bilateral of trapezius (Around Fengfu/Du16+ 1cm bilateral)

4. Acupuncture treatment:

- Apply piriforme needle of No. 28-30.

11.1. 寰枕间隙

A. 体位: 俯卧位，头前屈。

B. 体表标志：枕外隆凸、C2棘突、后发际、斜方肌。

C. 定点：

项部，当后发际正中之上3.5cm, 或枕外隆凸下缘之下2~3cm, 两侧斜方肌之间凹陷处（相当于风府穴）定中点，中点两侧旁开约1cm左右处各取一点，共3点。采取斜刺手法。

D. 针灸治疗：

建议使用至少28~30号针，以达到松解目的。

Treatment 治疗

1.2. Atlantoaxial joint 寰枢关节

1. Patient prone.
2. **Landmark:** C2 spinous process.
3. **Points locations:**

a. 1 point on the C1~C2 interspinous ligament, + 1 point on the safety area (1.5~2.5cm) bilateral, total will be 3 points.

b. 1 point on the C2~C3 interspinous ligament, + 1 point on the safety area (1.5~2.5cm) bilateral, total will be 3 points.

4. **Acupuncture treatment:**

a. C1~C3 interspinous ligament insertion: perpendicular 3~5mm.

b. Articular joints: Perpendicular 1cm.

c. Apply the piriforme needle No. 28~30.

11.2. 寰枢关节

A. 体位: 俯卧位。

B. 体表标志： C2棘突。

C. 定点：

1. C2棘突上缘一点（C1~C2棘间韧带），两侧旁开1.5~2.5cm各一点（棘突外上缘），共3点。
2. C2棘突下缘一点（C2~C3棘间韧带），两侧旁开1.5~2.5cm各一点（后关节突关节囊），共3点。

D. 针灸治疗：

1. C1~C3棘间韧带:直刺3~5mm。后关节突关节囊: 直刺1cm.
2. 建议使用至少28~30号针，以达到松解目的。

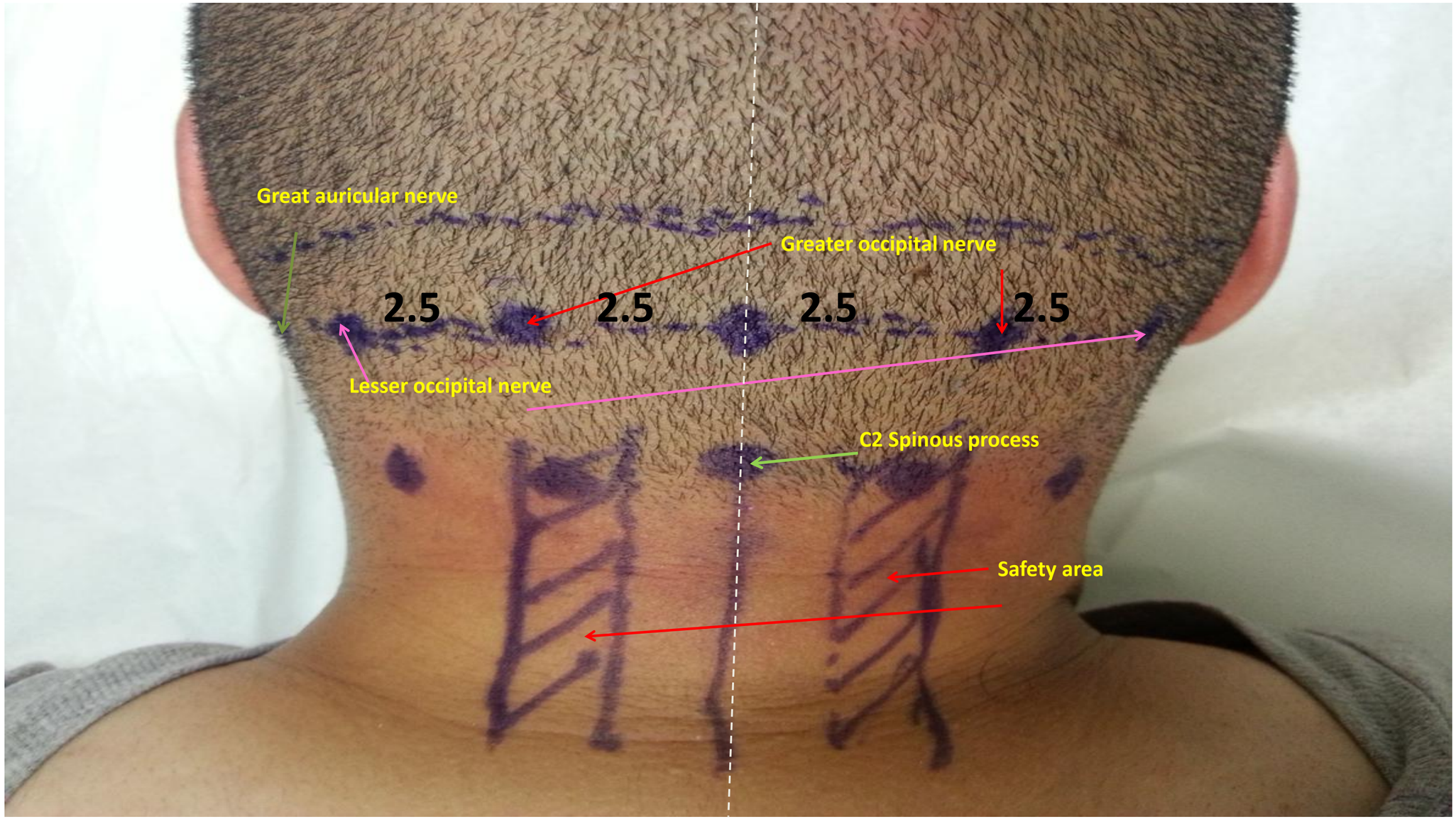
Great auricular nerve
Greater occipital nerve
2.5
2.5
2.5
2.5
Lesser occipital nerve
C2 Spinous process
Safety area

Middle ganglion treatment area
颈中神经节治疗区

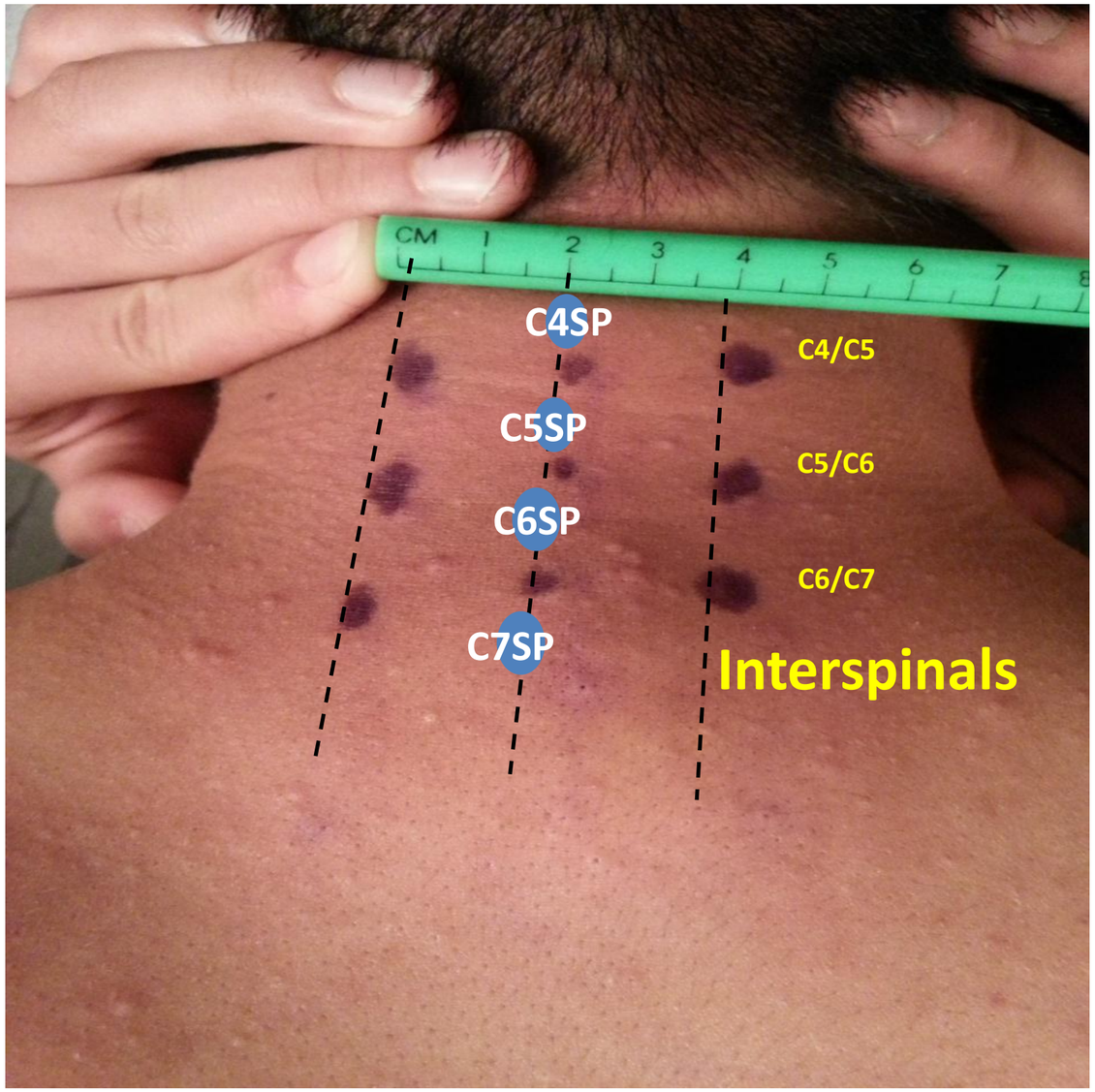

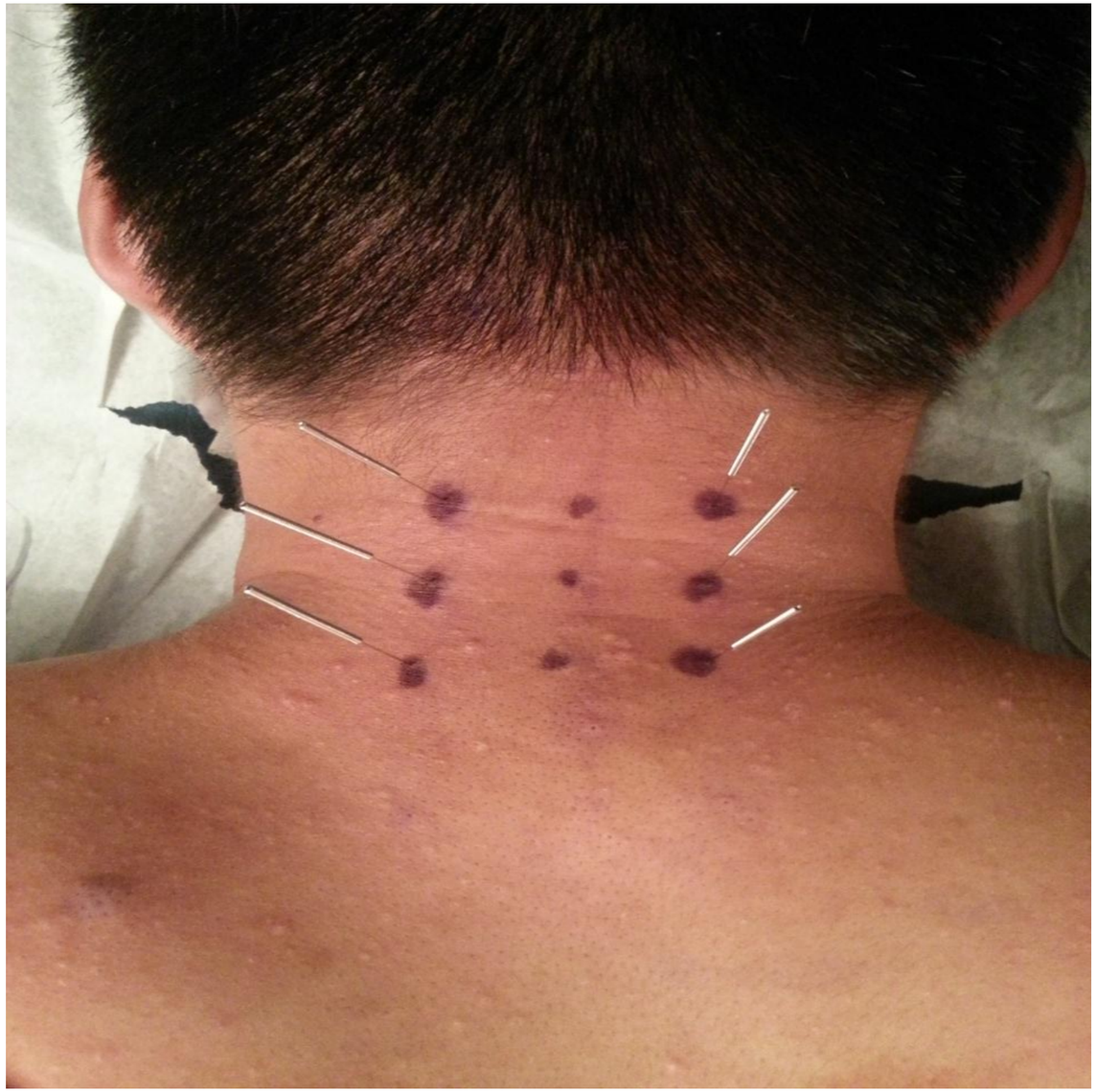

Treatment 治疗

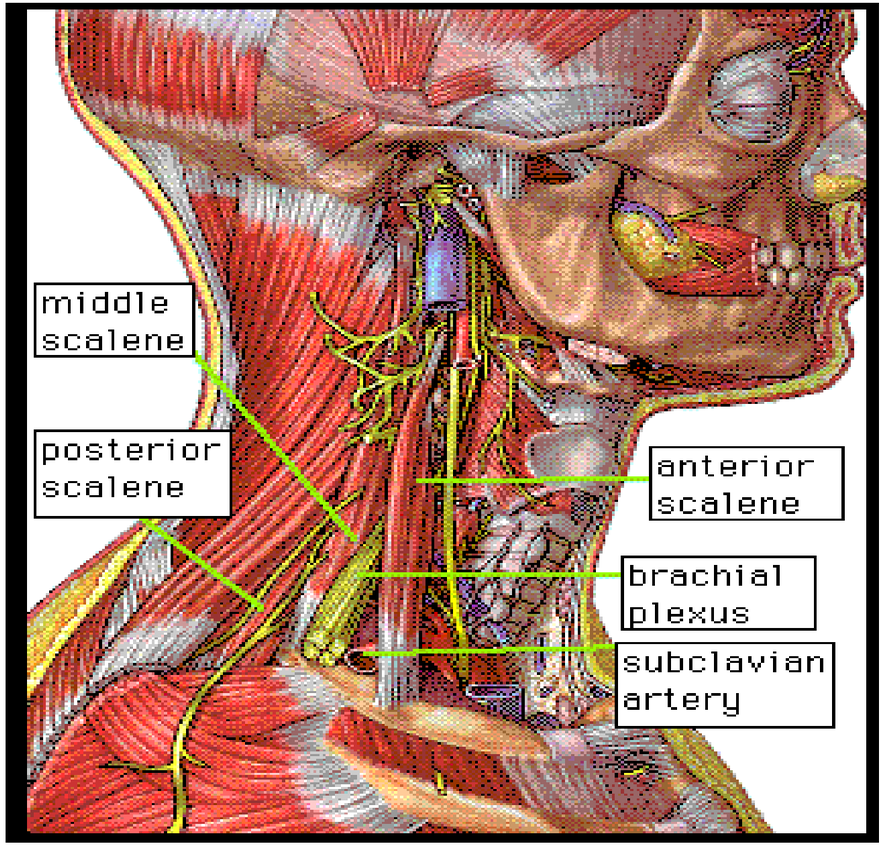

3. C5/C6, C6/C7, C7/T1 uncovertebral joints (Cervical 9 points)

3. C5/C6, C6/C7, C7/T1 后关节 （颈9针)

Inferior ganglion/ Stellate ganglion treatment area

颈下神经节/星状神经节治疗区

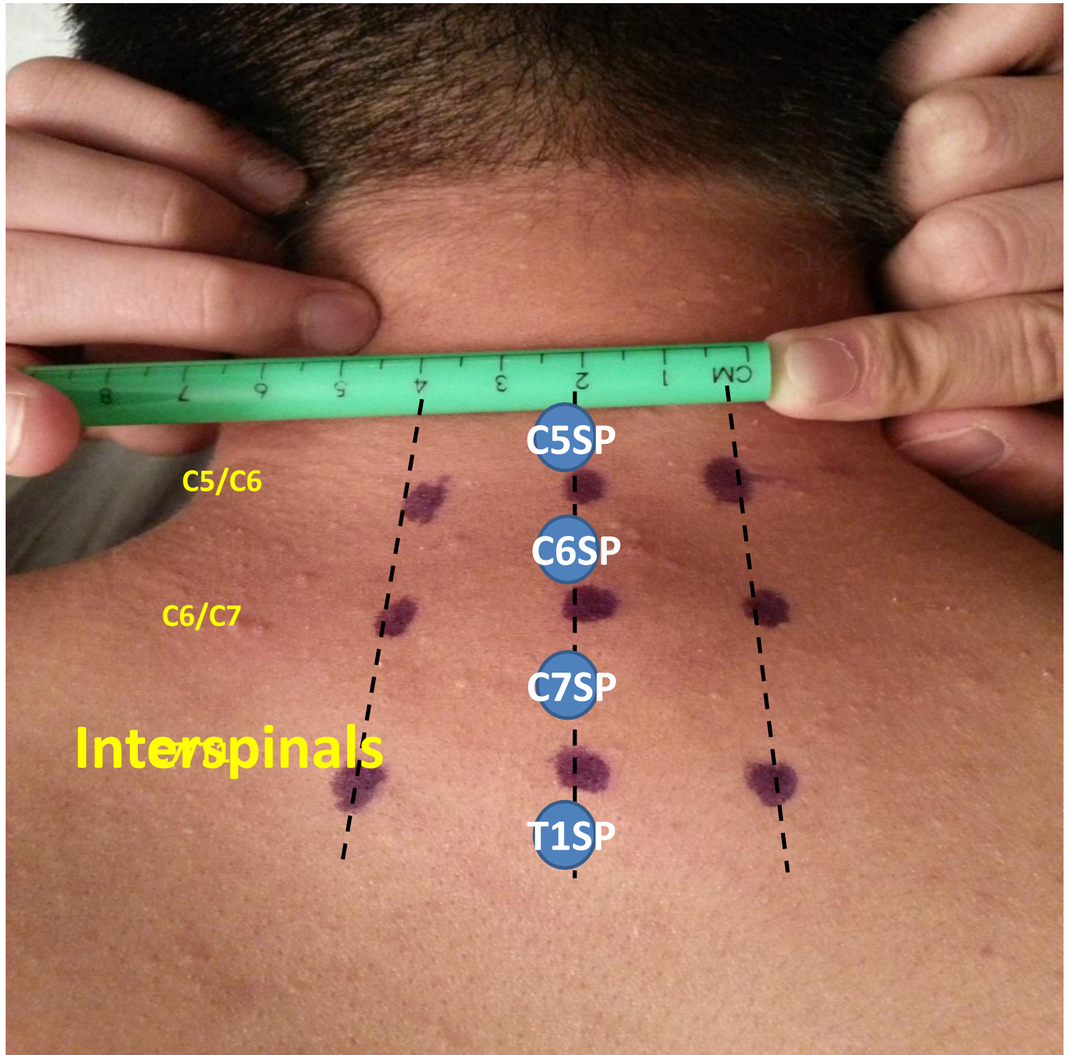

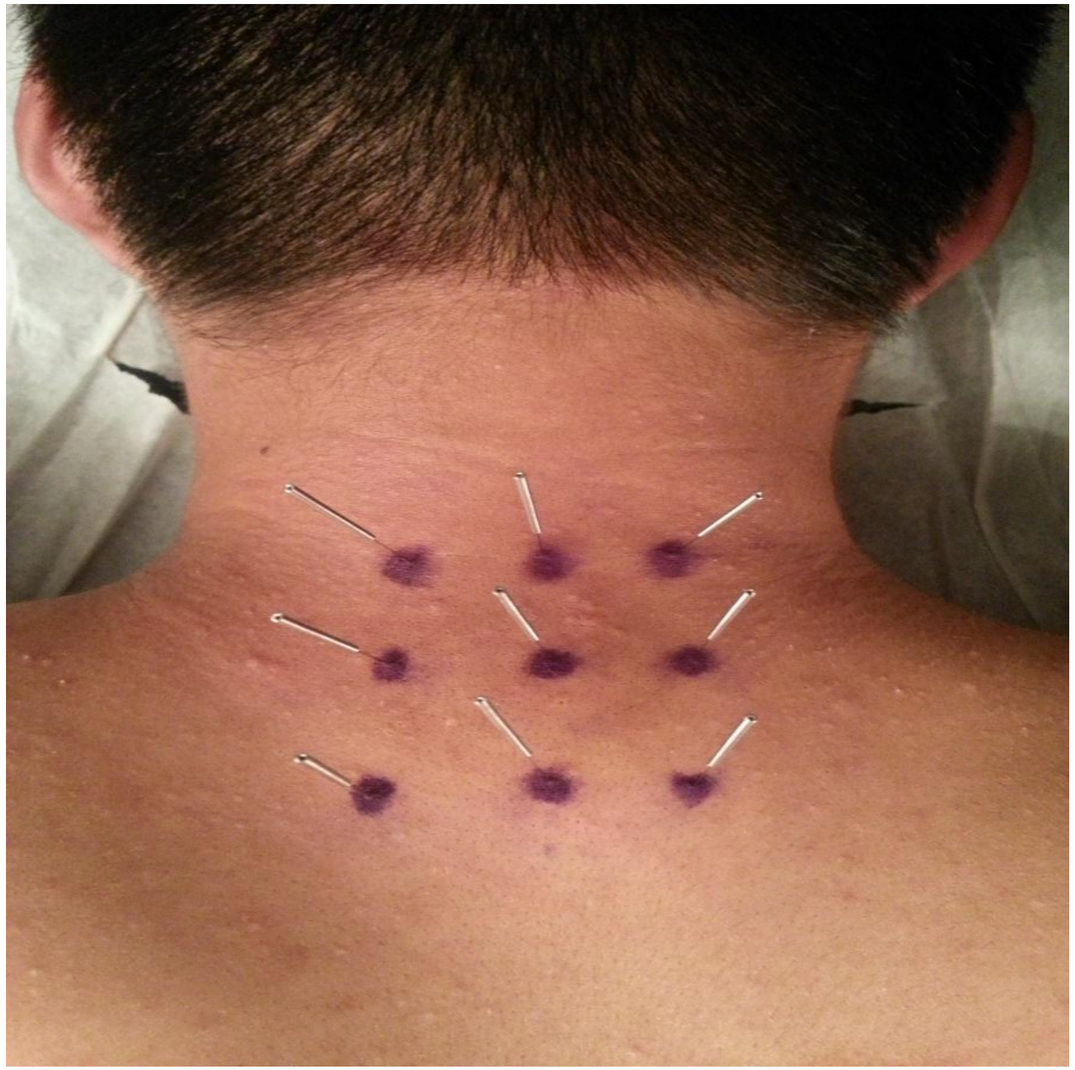

Treatment 治疗

4. Greater occipital nerves (above of Fengchi GB20)

枕大神经点（风池穴上部）

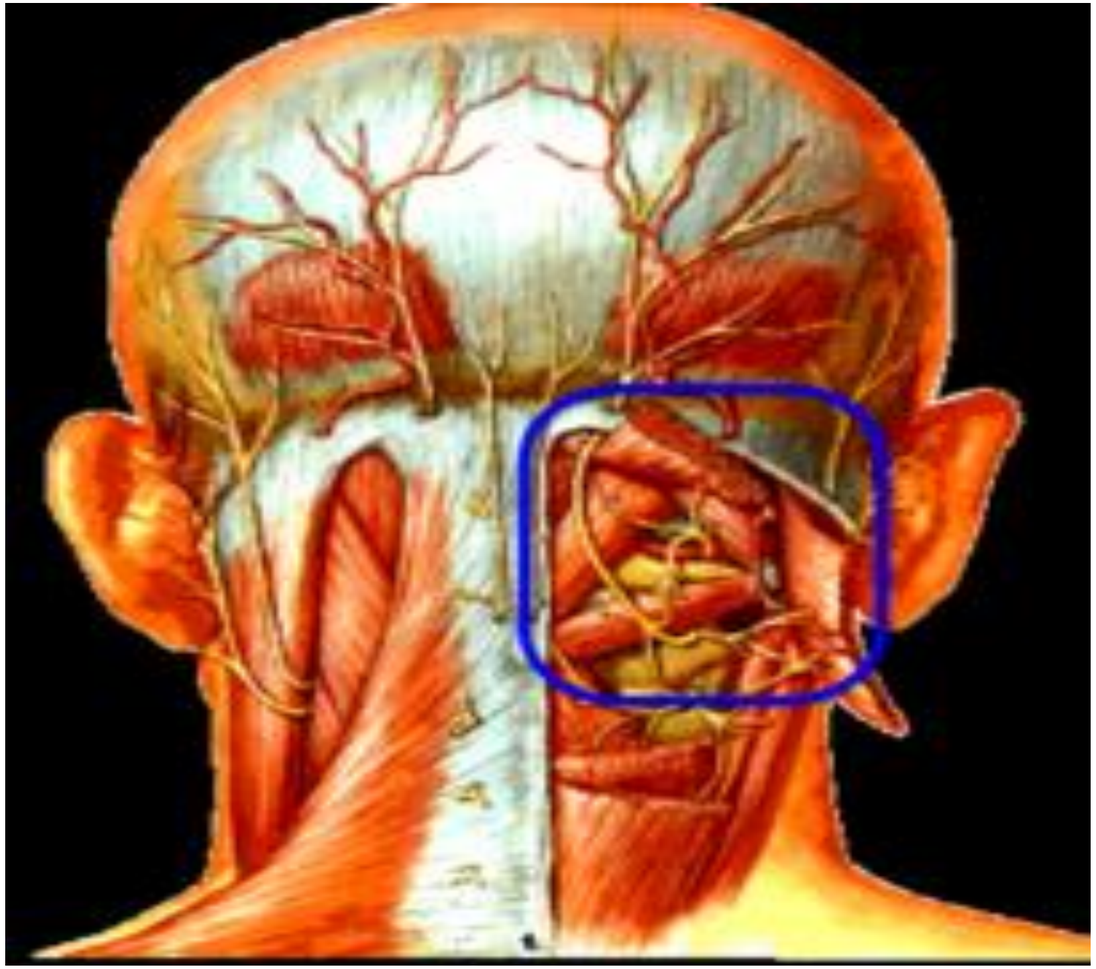

Greater occipital nerve (Fengchi GB20)
枕大神经点（风池穴）

Cervical Spondylosis
Nuchal type
颈型颈椎病

5 points upon 3 acupoints

3 Acupoints: UB10, Du14, SJ15

5 points: UB10(bilateral), SJ15 (bilateral), Du14

三穴五点

三穴：天柱、大椎、天髎

五点：天柱（双侧)、天髎（双侧)、加大椎

Cervical Spondylosis
Nuchal type 颈型颈椎病

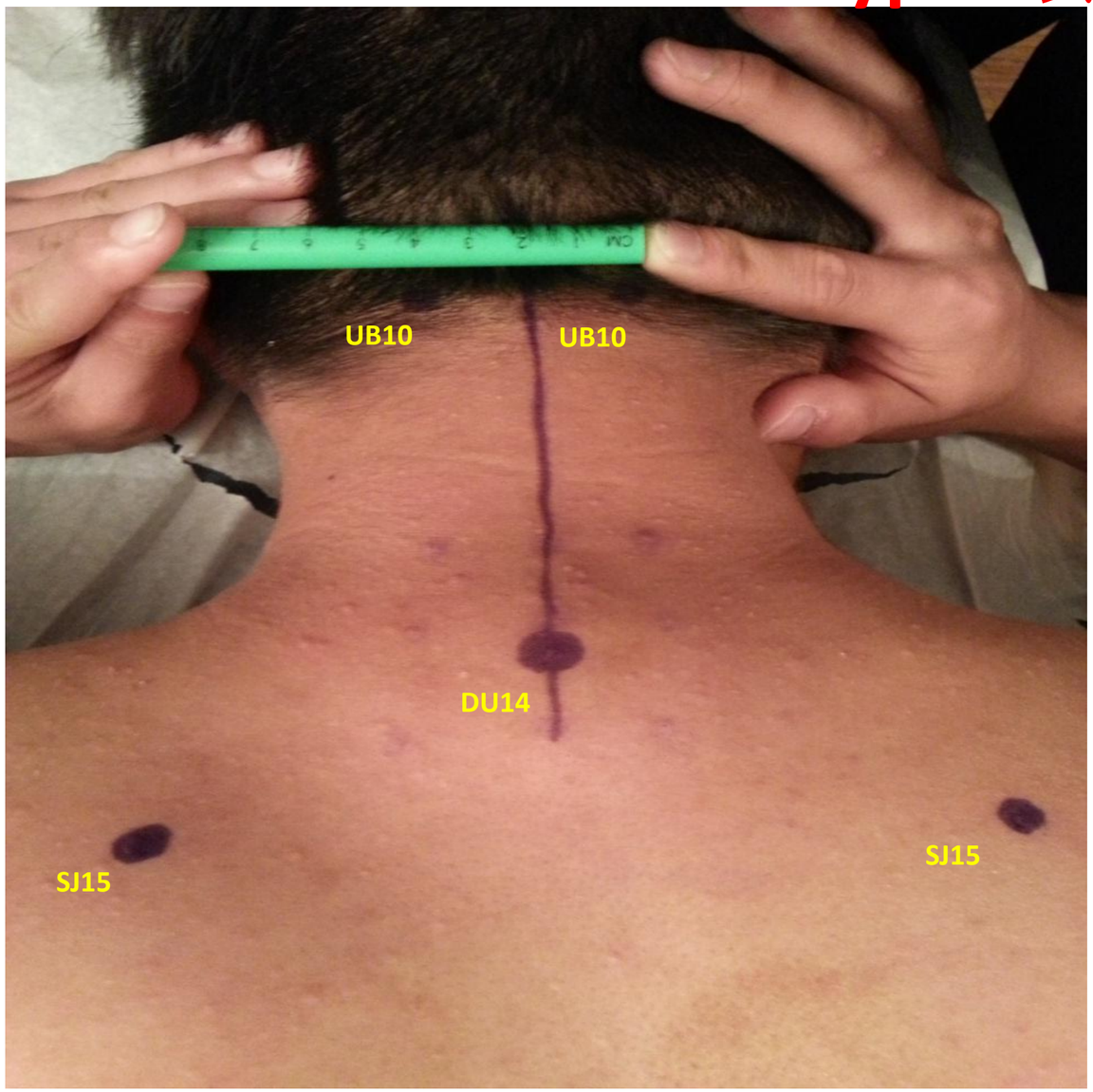

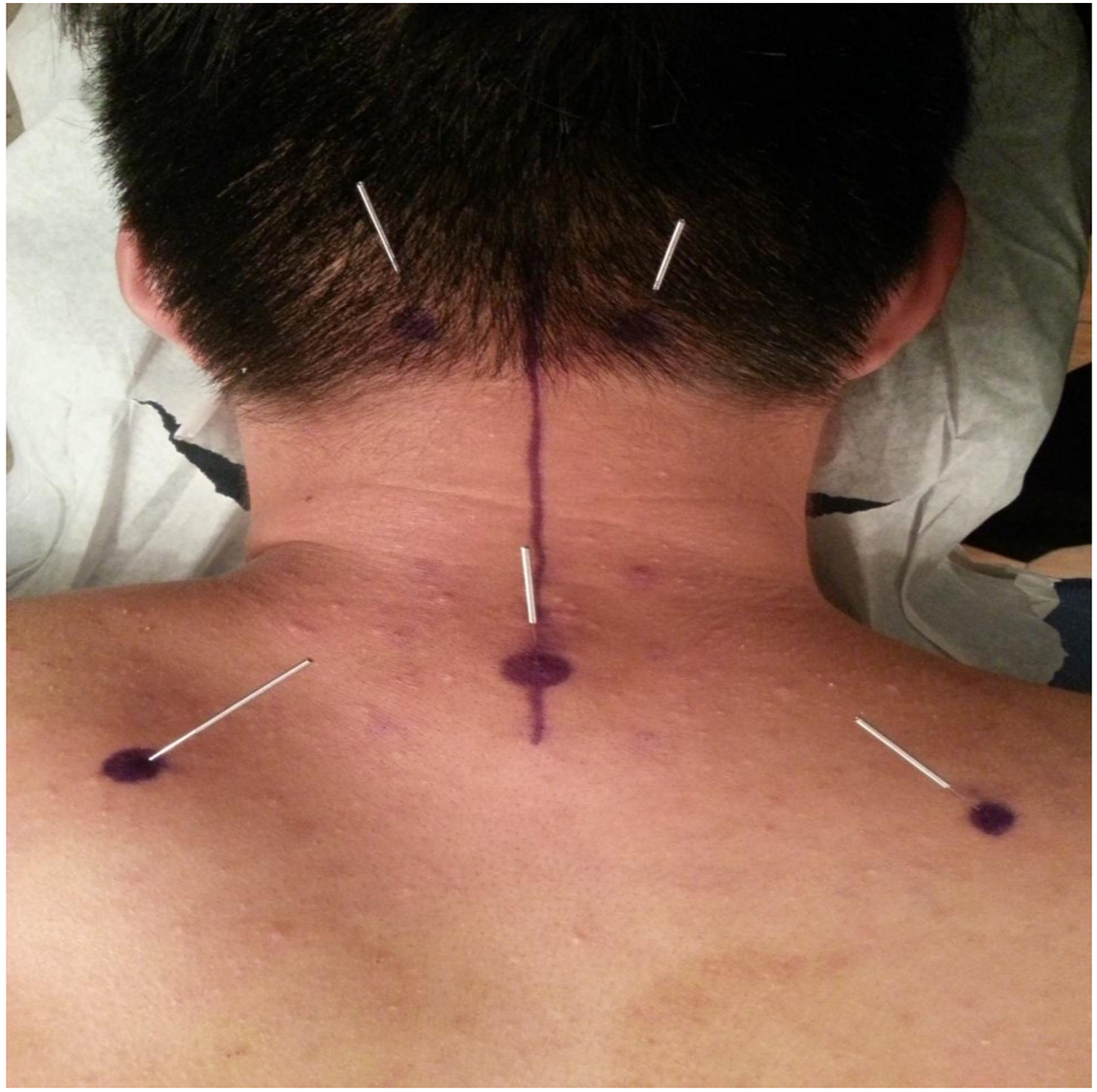

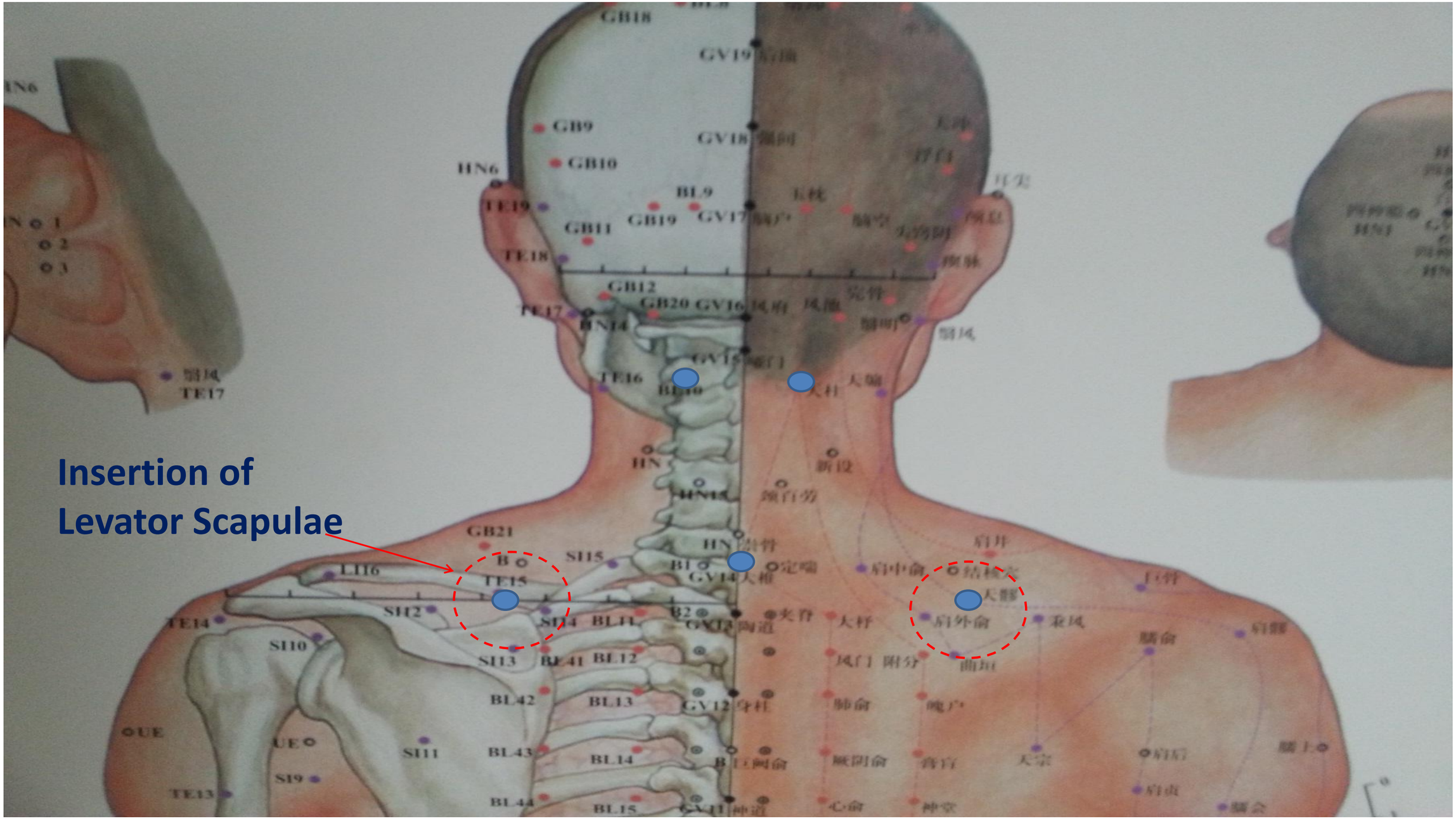
Insertion of
Levator Scapulae
GB18
GV19
GB9
GV18
GB10
HN6
BL9
TE19
GB19
GV17
GB11
TE18
GB12
GB20
GV16
TE17
HN14
TE16
BL10
HN
HN15
GB21
SI15
LI16
TE15
SI2
SI4
BL11
TE14
SI10
SI13
BL41
BL12
BL42
BL13
GV12
UE
SI11
BL43
BL14
SI9
TE13
BL44
BL15
GV11
GV15
GV14
B2
BL1
HN
SI1
BL1
天柱
风池
肩井
天宗
后外俞
肩俞
肺俞
魂户
心俞
神堂
膈俞
肩贞
天髎
曲垣
风门
阳分
夹脊
大杼
定喘
后中俞
后井
肩髎
肩贞
肩外俞
天宗
肩井
肩髎
肩贞
肩会

Cervical pain also related to Lumbosacral pain

Cervical pain also related to Lumbosacral pain

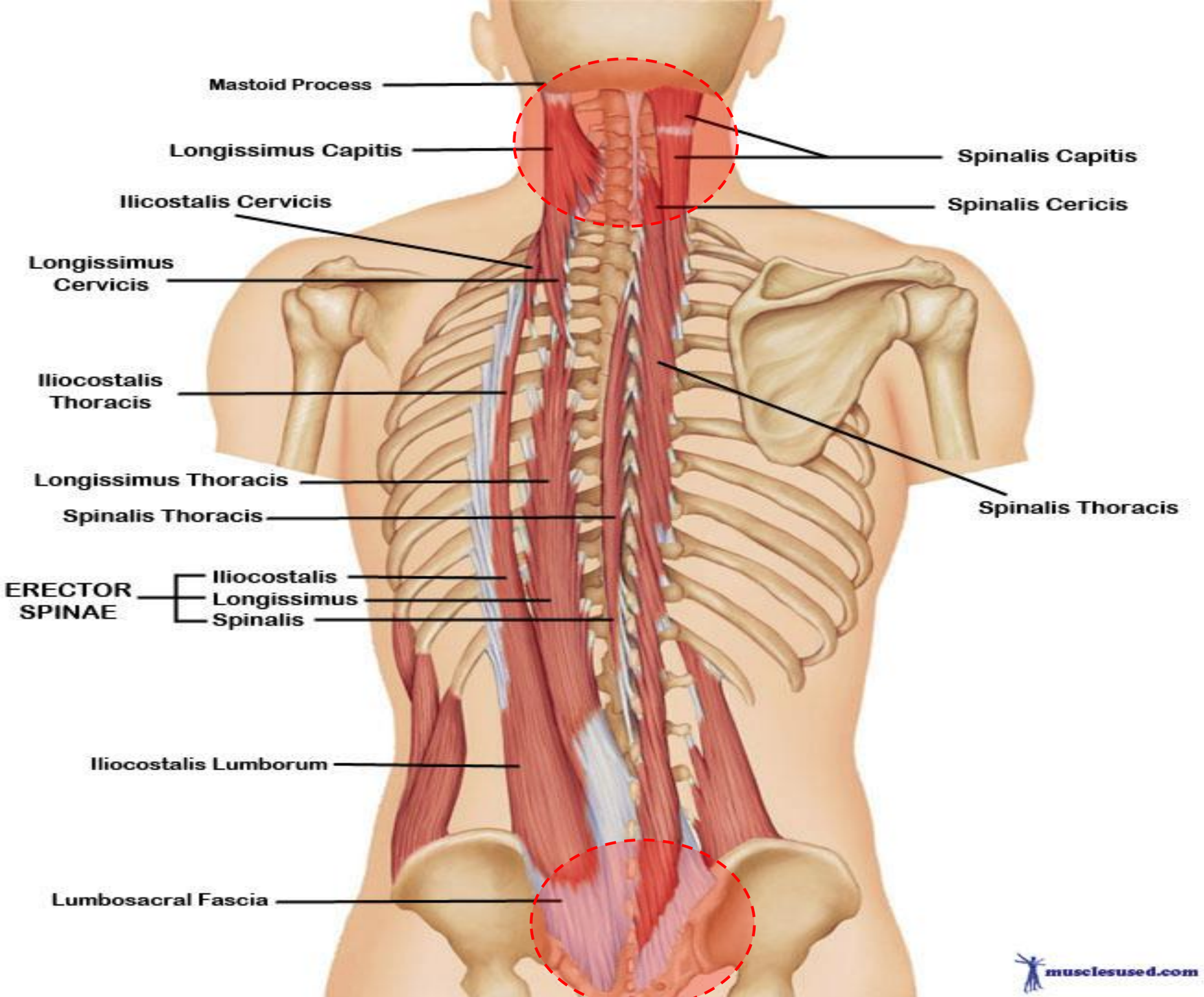
Mastoid Process
Longissimus Capitis
Spinalis Capitis
Ilicostalis Cervicis
Spinalis Cericis
Longissimus Cervicis
Iliocostalis Thoracis
Longissimus Thoracis
Spinalis Thoracis
Spinalis Thoracis
ERECTOR SPINAE
Iliocostalis
Longissimus
Spinalis
Iliocostalis Lumborum
Lumbosacral Fascia
musclesused.com

Dorsal muscles 背部肌群

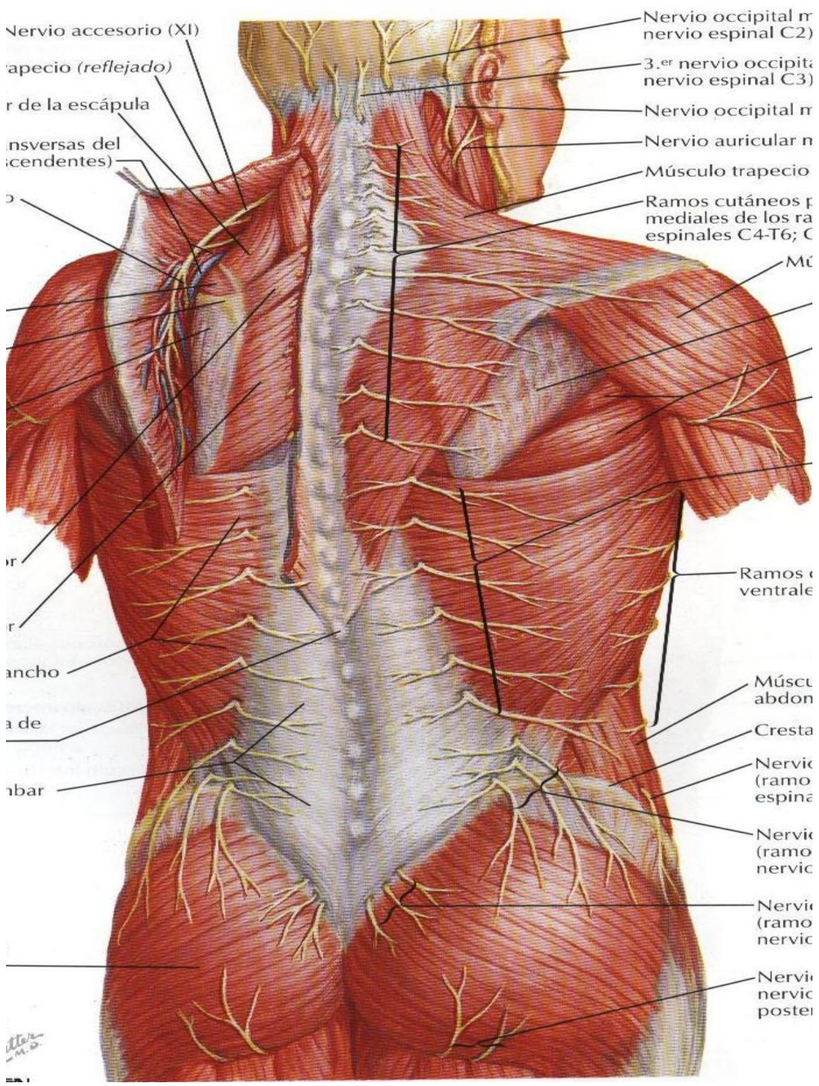

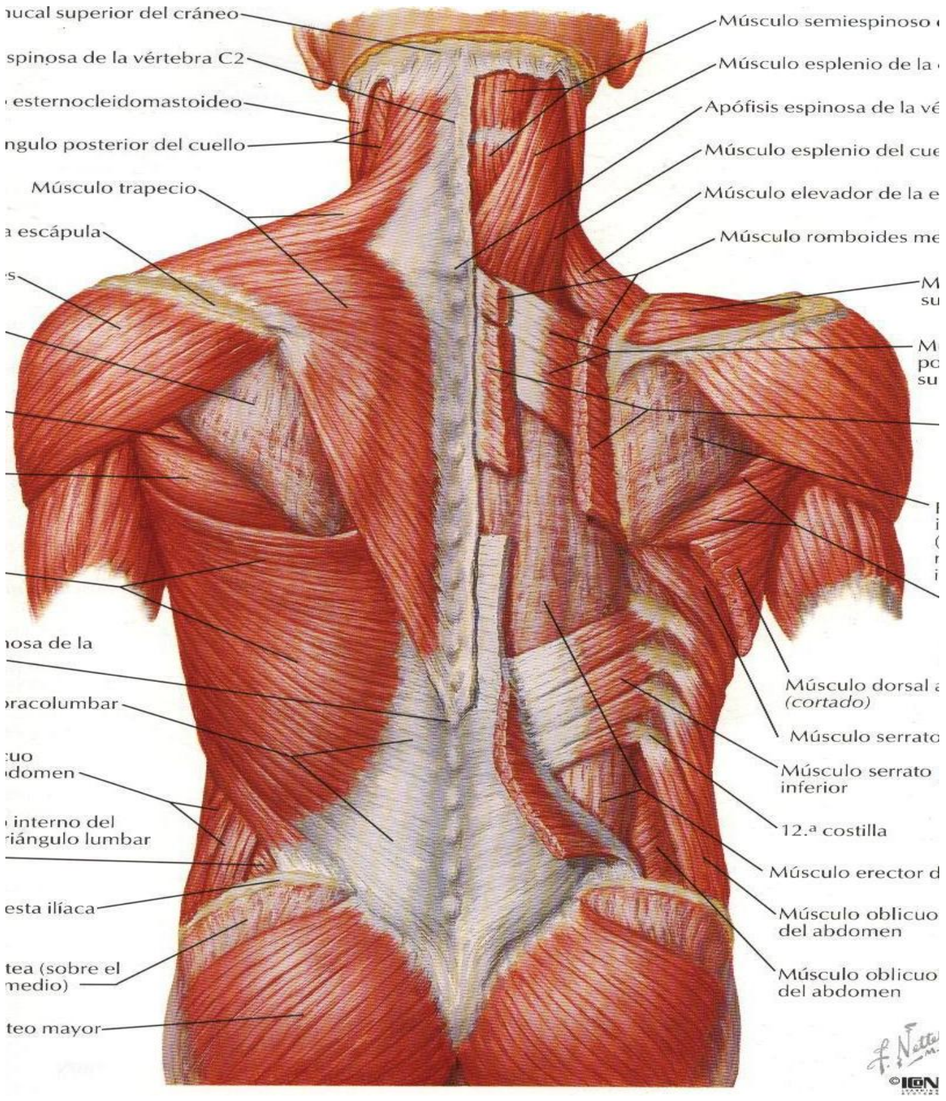

Sacral nerves compression induced diseases
骶部神经卡压引起之疾病

- Gynecology, reproduction, urinary system.
- Low back pain.
- Sciatic pain.
- Hip pain.
- Knee pain, etc.
- 妇科、生殖、泌尿
- 下腰部疼痛
- 坐骨神经痛
- 臀、膝痛

Adjustment technique:

✓ **Cervical, thoracic and lumbar vertebrae adjustments.**

Acupotomology 针刀医学

- Relieve the soft tissues contractures, nerves compression, spurs, bursitis, tendinitis, tenosynovitis, myositis ossification, chronic strains, etc.

- Specialties: Ortho-traumatology, surgery, pediatric, gynecology, internal medicine, etc.


BREAK
TIME

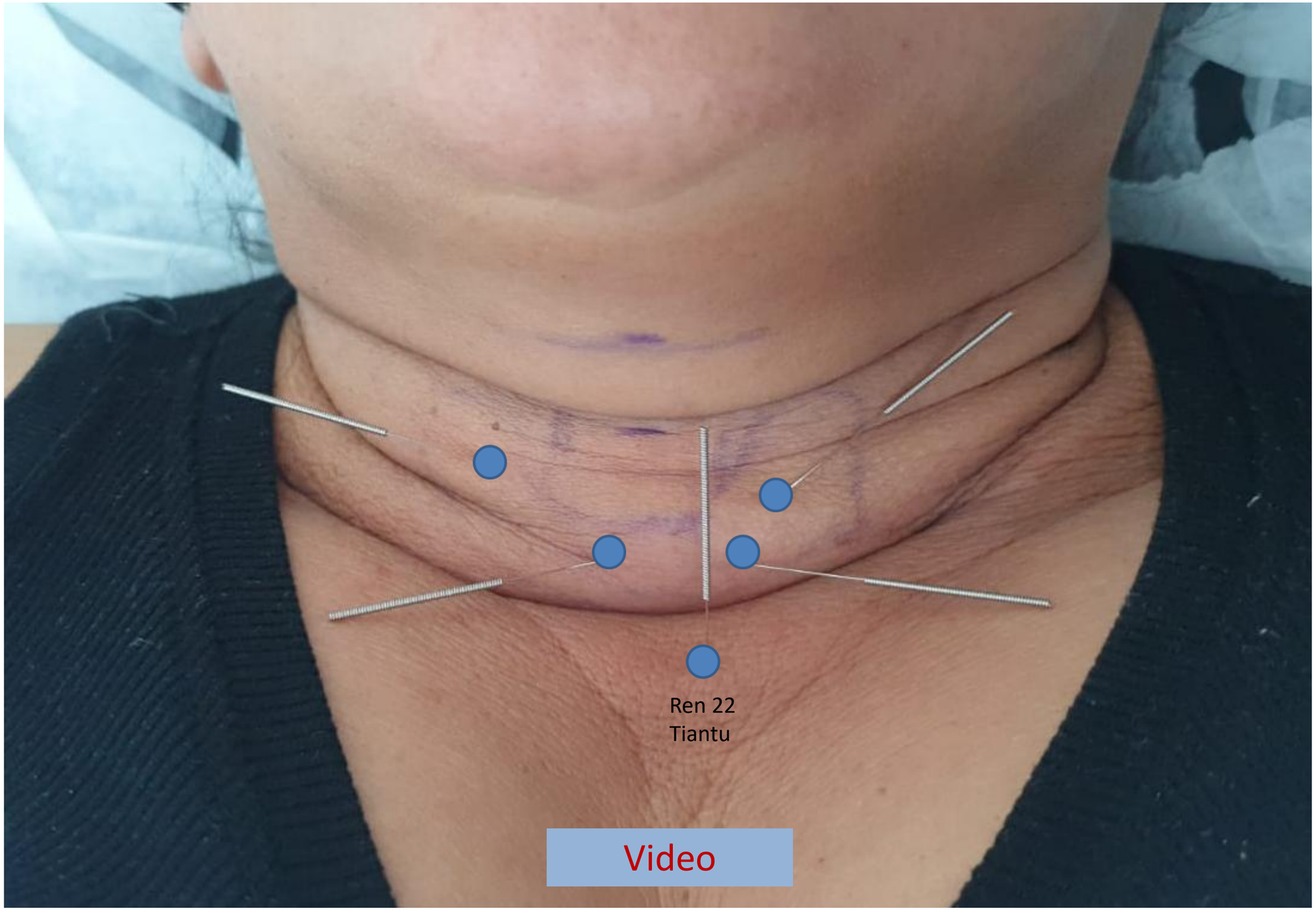
Ren 22
Tiantu
Video


Video
Ren 22
Tiantu

Video 1

Video 2

Video 3

Video 4

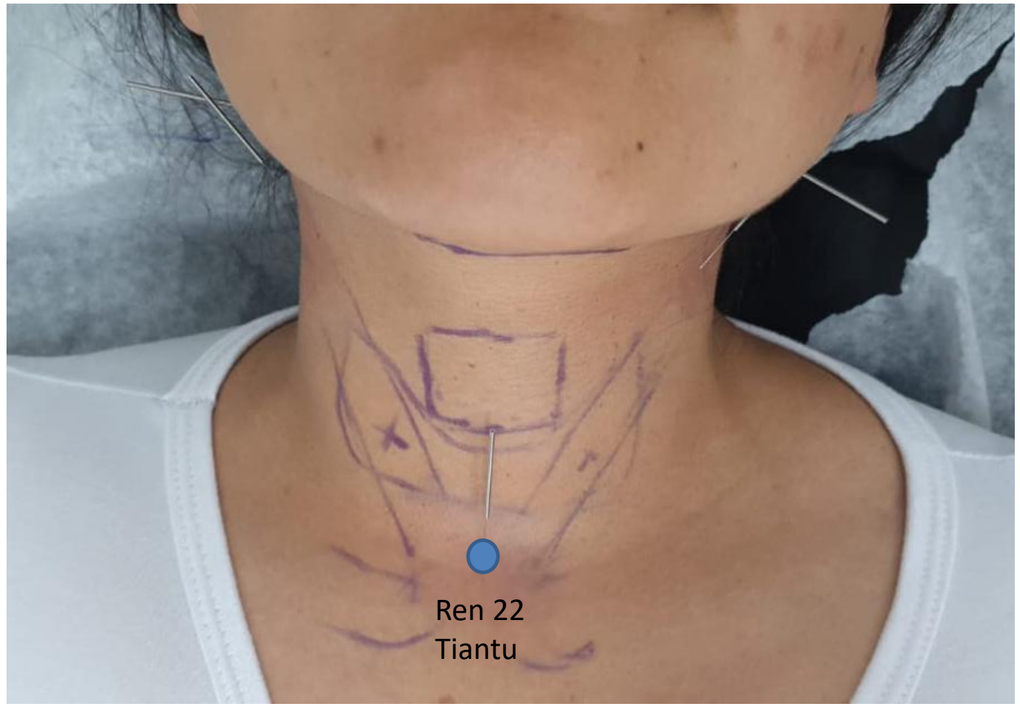

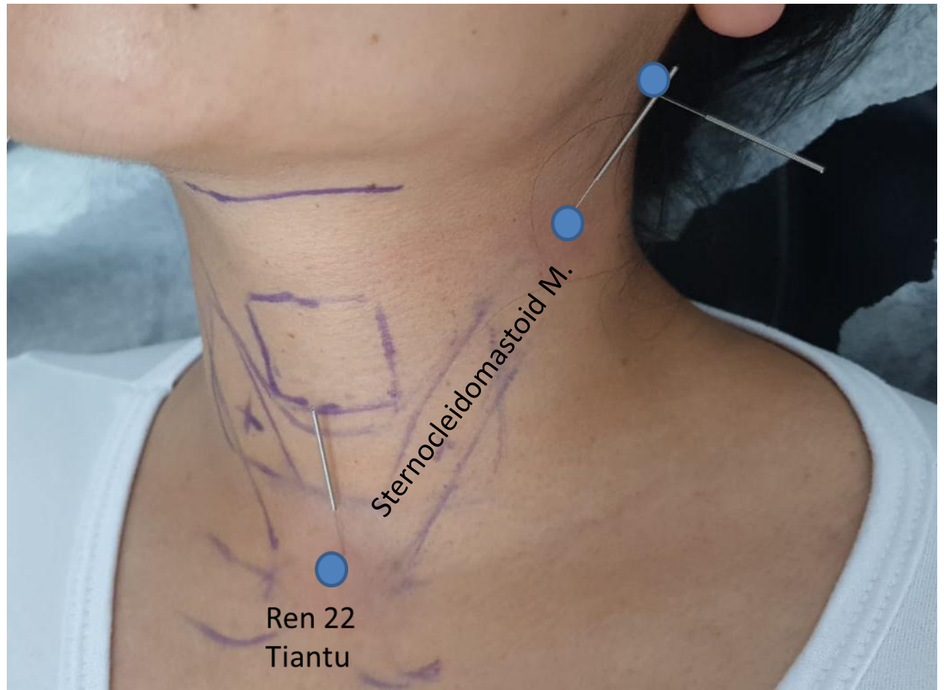

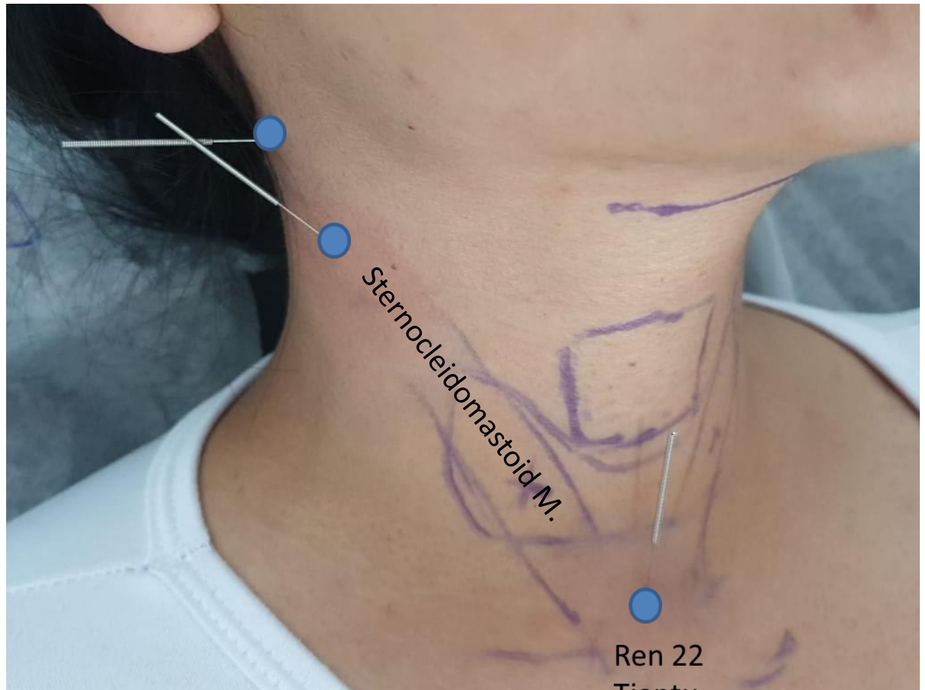

metric 1
2
3
4
5
6

metric 1
2
3
4
5
6

Nov. 2017 - Hyperthyroidism

Certus® LABORATORIO CLÍNICO

Informe de Resultados

MEDICAL SERVICES INTERNATIONAL, S.A. de C.V.
Responsable: Q.F.B. Ma. Eugenia Acevedo M.

Nombre del Paciente: [redacted] LETICIA
No. de Folio: 7128361

Pág: 4/5

Reporte	Edad	Género	Dirigido a
Final	54 Años	FEMENINO	RAMIREZ Y VEANA FELIPE
Toma de muestra	Recibido	Reportado	No. de Cuenta
16/11/2017 9:39AM	16/11/2017 9:29AM		0126F CERTUS LABORATORIO HIPODROMO (F)

Exámen	Resultado	Unidades	Intervalos Biológicos de Referencia
CO2 (CALCULADO)	19.4	mEq/L	12-33
CALCIO	9.5	mg/dL	8.4 - 10.2
FOSFORO	2.8	mg/dL	2.3 - 4.7
PROTEINAS TOTALES	7.1	g/dL	6.3 - 8.3
ALBUMINA	4.1	g/dL	3.5 - 5.0
GLOBULINAS	3.0	g/dL	2.0- 5.0
RELACION A/G	1.4		0.9-3.5
AST (ASPARTATO AMINOTRANSFERASA)	19	U/L	2-50
ALT (ALANINO AMINOTRANSFERASA)	51	U/L	2 - 60
FOSFATASA ALCALINA	90.9	U/L	40 - 150
BILIRRUBINA TOTAL	0.59	mg/dL	0.10 - 1.40
DHL (DESHIDROGENASA LACTICA)	147	U/L	125 - 220
GAMMA GLUTAMIL TRANSPEPTIDASA	* 39	U/L	9 - 36
HIERRO	109	µg/dL	50 - 170
TRIGLICERIDOS	150	mg/dL	50-150
COLESTEROL TOTAL	188	mg/dL	50-200
COLESTEROL HDL	* 36.0	mg/dL	Mayor de 40
COLESTEROL LDL (CUANTIFICADO)	* 135.6	mg/dL	MENOR O IGUAL A 129
INDICE COLESTEROL/HDL (CALCULADO)	* 5.2		MENOR DE 4
INDICE LDL/HDL (CALCULADO)	* 3.8		MENOR DE 3

Nota: Para realizar la conversión de unidades convencionales a unidades del Sistema Internacional (SI), multiplique el resultado por los siguientes factores:

Examen	Factor de conversión	Unidad SI	Examen	Factor de conversión	Unidad SI
Ácido úrico	0.05948	mmol/L	Albúmina	10.0	g/L
Bilirrubina Total	17.1	µmol/L	Calcio	0.25	mmol/L
Colesterol	0.02586	mmol/L	Creatinina	88.4	µmol/L
Fósforo	0.3229	mmol/L	Glucosa	0.05551	mmol/L
Proteínas totales	10.0	g/L	Triglicéridos	0.01129	mmol/L
Nitrógeno Ureico	0.357	mmol/L	Hierro	0.1791	µmol/L
Sodio, potasio, cloro	1.0	mmol/L	HDL	0.02586	mmol/L
LDL	0.02586	mmol/L	Bilirrubina Directa	17.1	µmol/L

T4 LIBRE (TIROXINA LIBRE)

T4 LIBRE	* 2.41	ng/dL	0.7 - 1.48

Los resultados y límites de referencia de este examen son reportados en unidades convencionales, para realizar la conversión a unidades del Sistema Internacional (SI) multiplique el resultado en ng/dL por el factor de 12.87 para convertir las unidades a pmol/L.

METODO: QUIMIOLUMINISCENCIA

TSH (HORMONA ESTIMULANTE DE TIROIDES)

TSH	* MENOR DE 0.0047	µUI/mL	0.35 - 4.94

Los resultados y límites de referencia de este examen son reportados en unidades convencionales, para realizar la conversión a unidades del Sistema Internacional (mUI/L) multiplicar por el factor de conversión que es 1.0

Este informe de resultados electrónico es de carácter informativo y no sustituye el informe original.

LOS RESULTADOS FUERA DEL LIMITE DE REFERENCIA SE IDENTIFICAN CON UN ASTERISCO (*)

Por la importancia de la prevención y el monitoreo de su salud, permítanos rodearle de beneficios.
Conozca nuestro programa "Círculo Elite" en www.certuslab.com.mx

PREMIOS DE CALIDAD

F-012-OP Rev. 03 22-Dic-2017

Sep. 2021 - normal

Laboratorios GAMBOA — Tu laboratorio de confianza —

Acreditados por: ema LABORATORIO CLÍNICO ACREDITADO CL-120

El alcance de las pruebas acreditadas, lo encuentra en www.labgamboa.com

www.labgamboa.com
/labgamboa
/laboratorios gamboa

Registro No.:	2021090407860	Cliente:	SIN ORDEN
Nombres:	[redacted] LETICIA	Fecha de nacimiento:	13/11/1963
Sucursal:	PLAZA EMELY	Edad: 57 Años	Sexo: Femenino
Medico:	A QUIEN CORRESPONDA	Fecha Ingreso:	04/09/2021 10:25
Comentario:		Fecha Impresión:	04/09/2021 13:24

PRUEBA	RESULTADO	UNIDAD	VALORES DE REFERENCIA
- T4 LIBRE Método: Inmunoanalisis Quimioluminiscente de Microparticulas (CMIA) Tipo de Muestra: Suero	1.27	ng/mL	0.78 - 2.19
- TSH Método: Inmunoanalisis Quimioluminiscente de Microparticulas (CMIA) Tipo de Muestra: Suero	0.630	mIU/L	0.465 - 4.680

Valido: AMY CAROLINA ZAZUETA RUESGA Q.B.C.
** Prueba Acreditada*
- Prueba No Acreditada
++ Prueba Subrogrados

OK

Este resultado de estudio es válido para la muestra que está siendo registrada y procesada en este momento, está condicionado a la variabilidad biológica y al historial clínico del paciente.

RESPONSABLE DEL LABORATORIO
Q.B.P. FEDERICO GUILLERMO GAMBOA COVARRUBIAS
D.G.P. 5618231

RESPONSABLE SANITARIO
Q.F.B. CLAUDIA BEATRIZ TORRES PRECIADO
D.G.P. 2861973

*Resultado obtenido a través de internet

"Laboratorio Clínico Acreditado por EMA, A.C. con acreditación No. CL-120"
Puede consultar nuestro alcance de acreditación en www.labgamboa.com

Pagina 1 de 1

PLAZA EMELY (664) 681-5773 · SEGUNDA CENTRO (664) 685-8116 · ROSARITO (661) 612-6935 · OTAY (664) 647-0580 · REFUGIO (664) 102-6494 · PLAZA RIO (664) 975-3030 · PLAZA FINANCIERA (664) 634-1625
PLAYAS (664) 631-8630 · PAJARITA (664) 634-6688 · PACIFICO (664) 208-9616 · RIO (664) 634-2134 · MONARCA (664) 625-2742 · FUNDADORES (664) 634-4746 · CUCAPAH (664) 646-0111 · COLORADO (664) 629-4984

LGA-PO-RH-001-F09 Rev.4 20-01-2020

March 2024 - normal

INFORME DE RESULTADOS
MEDICAL SERVICES INTERNATIONAL, S.A. de C.V.

Certus® LABORATORIO

Nombre del paciente: LETICIA [redacted]
Folio: 003240312-0068
Clave de confirmación: GVUPO2

Pág. 1/

Reporte	Edad	Género	Dirigido a
Parcial	60 años	FEMENINO	A QUIEN CORRESPONDA .
Alta de orden	Toma de muestra	Reportado	No. de cuenta
12/03/2024 09:09:00 a. m.	12/03/2024 10:16:00 a. m.	12/03/2024 05:52:31 p. m.	6060-CERTUS LABORATORIO CLINICO (TE

Examen	Resultado	Unidades	Intervalos de Referencia Biológicos
TU GUIA 36			
BIOMETRIA HEMATICA			
CITOMETRÍA DE FLUJO CON FLUORESCENCIA / ENFOQUE HIDRODINÁMICO Y CORRIENTE ELÉCTRICA / HEMOGLOBINA SULFATO LAURICO SÓDICO.			
Muestra : SANGRE TOTAL			
GLOBULOS BLANCOS	6.86	x 10^3 / µL	3.98 - 10.04
GLOBULOS ROJOS	4.74	x 10^6 / µL	3.93 - 5.22
HEMOGLOBINA	14.50	g / dL	11.20 - 15.70
HEMATOCRITO	43.2	%	34.1 - 44.9
V.C.M.	91.1	fL	79.4 - 94.8
H.C.M.	30.6	pg	25.6 - 32.2
C.H.C.M.	33.6	g / dL	32.2 - 35.5
RDW-CV	12.1	%	11.7 - 14.4
MPV	10.4	fL	9.4 - 12.3
LINFOCITOS (%)	27.8	%	19.3 - 51.7
LINFOCITOS (ABSOLUTOS)	1.91	x 10^3 / µL	1.18 - 3.74
MONOCITOS (%)	9.0	%	4.7 - 12.5
MONOCITOS (ABSOLUTOS)	0.62	x 10^3 / µL	0.24 - 0.86
EOSINOFILOS (%)	2.00	%	0.70 - 5.80
EOSINOFILOS (ABSOLUTOS)	0.137	x 10^3 / µL	0.040 - 0.360
BASOFILOS (%)	0.40	%	0.10 - 1.20
BASOFILOS (ABSOLUTOS)	0.03	x 10^3 / µL	0.01 - 0.08
NEUTROFILOS (%)	60.5	%	34.0 - 71.1
NEUTROFILOS TOTALES (ABSOLUTOS)	4.15	x 10^3 / µL	1.56 - 6.13
PLAQUETAS	249.0	x 10^3 / µL	167.0 - 431.0
VELOCIDAD DE SEDIMENTACION GLOBULAR	7	mm / hr	0 - 29
FOTOMETRIA CAPILAR CUANTITATIVA.			
EXAMEN GENERAL DE ORINA			
Muestra : ORINA AL AZAR, ORINA EGO			
HEMOGLOBINA A1C			
CROMATOGRAFÍA DE LÍQUIDOS DE ALTA RESOLUCIÓN (HPLC).			
HEMOGLOBINA A1C	5.4	%	3.5 - 5.7
INTERPRETACIÓN:			

Los valores de HbA1c de 5.7- 6.4 % indican un mayor riesgo de desarrollar diabetes mellitus. Valores de HbA1c mayores o iguales a 6.5 % son diagnósticos d diabetes mellitus.
Referencia: Asociación Americana de Diabetes (ADA) Diabetes Care 2023.

OK

T4 LIBRE (TIROXINA LIBRE)	1.52	ng / dL	0.78 - 2.19

Muestra : SUERO
RESULTADOS HISTÓRICOS
T4 LIBRE 22 Sep 2023 = 1.26 07 May 2023 = 1.26

OK

TSH (HORMONA ESTIMULANTE DE TIROIDES)	3.74	µUI/mL	0.46 - 4.68

RESULTADOS HISTÓRICOS
TSH 22 Sep 2023 = 2.11 20 May 2023 = 1.500

VITAMINA D (25-HIDROXI) QUIMIOLUMINISCENCIA AMPLIFICADA	27 •	ng / mL	30 - 100
QUIMICA SANGUINEA 36			
Muestra : SUERO			
GLUCOSA	102 •	mg/dL	74 - 99
NITROGENO UREICO	14.3	mg / dL	9.8 - 20.1
CREATININA	0.71	mg/dL	0.40 - 0.91

After 3 months of Acupuncture treatment, recover the normal thyroid condition.


Q&A
dreamstime

Reference:

1. Temas Selectos en Acupotomologia, Song Qinfu, Mei Hung Lee Lai, Mexico, 2022.
2. The Principles of Acupotomology, Zhu Hanzhang, People Publishing Medical House, 2002.
3. Acupotomology for Cervical Spondylosis treatment, Wang Wende/ Liu Baizhi, People Publishing Medical House, 2008.
4. Acupotomology, Cui Xiufang, Science Publishing, 2009.
5. Spine Etiology Therapy, Weizheng, Commercial Press, 1987
6. Spinal System Diseases, Huang Kaibin/ Zhou Zhonghuan, World Medicine Info, 2003.
7. Atlas of Human Anatomy, Frank H. Netter, Netter Reference, 5 th. Edition.

Thank you

for your attention

Mei Hung Lee Lai, PhD, LAc

Email:
meihleelai@gmail.com